

# NEUROIMAGE

A long-exposure photograph of a multi-tiered waterfall. The water is blurred, creating a sense of continuous motion. On the right side, a small, bright orange and yellow fire burns in a dark, recessed area of the rock. The overall scene is dramatic and somewhat somber.

IN MEMORIAM



A grid of skull X-rays is displayed on a light box. The text is overlaid on the grid. At the bottom, a person's hand is visible, resting on a control panel with a red button and a keyboard.

PHYSICIAN

TEACHER

COLLEAGUE

MENTOR

FRIEND

FAMILY MAN

GENTLEMAN

# ACKNOWLEDGEMENTS

---

Jean-Paul Acco

Dr Michel Aube

Dr. Makki Almuntashri

Dr Karel ter Brugge

Robin Granich

François Larosée

Dr Sunithi Mani

Dr André Olivier



# SUNRISE CONSULTATIONS

---

## Dr Michel Aube

I had the privilege to interact with Dr Denis Melançon for more than 40 years.

The best time was at 6:45am. I had just come to work and needed some clinically relevant interpretation on a radiology report that had reached my office the day before.

On the 5th floor alone in the radiology department, Denis was just starting to taste his morning coffee at the sound of some classical music.

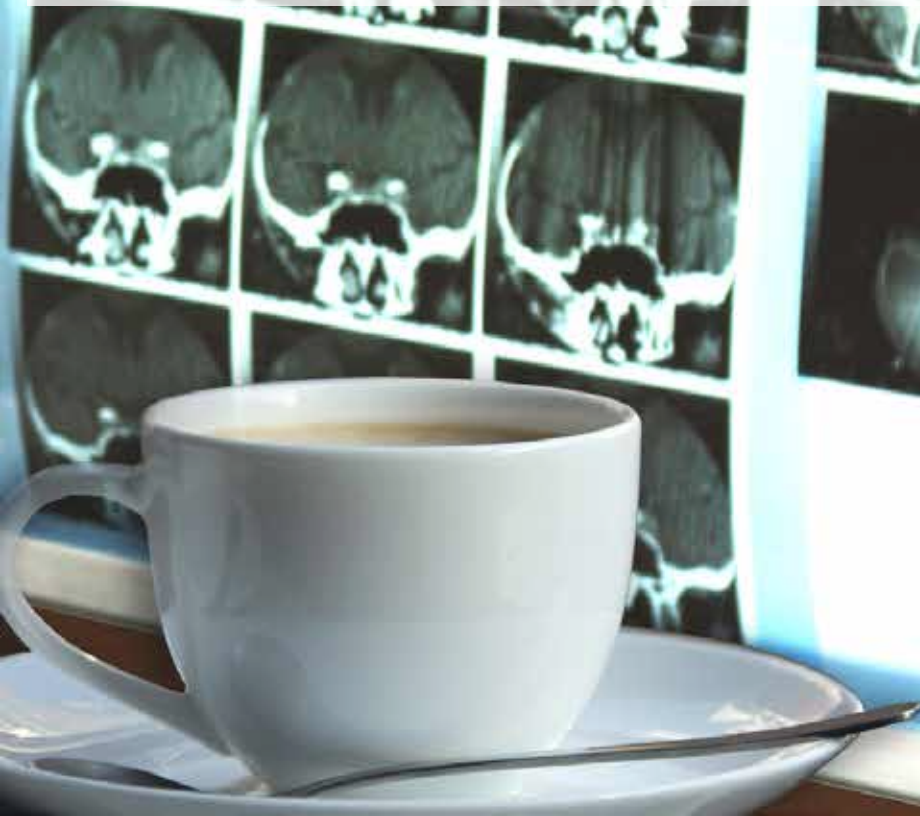Knocking at his door gave me the impression that I was perhaps interfering with his collection of radiological data. Denis was indeed a true erudite in his field. In no way was I ever not reassured by his interpretation of radiological data.

His knowledge and passion to share, it was much beyond the still trivial standards of the faculty of medicine.

We do rarely come across giants of such stature whose influence has contributed so much in a silent way to the perpetuation of the fundamental values of what medicine is all about.

Denis, thank you for your knowledge, expertise and generosity.

Michel Aubé md



# THE PERFECT TEACHER- A PATIENT GUIDE

## Dr Sunithi Mani

A recent Medical graduate from India, I went to Montreal to be with my husband, Dr Mathew Alexander who was doing his fellowship in Neuromuscular Neurology at the MNI in 2000. In a cold country and being extremely lonely, he insisted I should go to Montreal and I was looking for an observership to help in my career. Mathew met Dr Melançon and told him the situation and within an hour I had a letter from him welcoming me to be an observer at the Neuro!



I enjoyed my time at the Neuro mainly because of the great teacher that he was. He had a weekly routine- he would teach brain cutting, see interesting cases with the residents, discuss difficult cases with the clinicians and remain unruffled all through. The office staff and secretaries loved him as he was their champion. He would greet me with a kiss on each cheek and ask about my family. When he was on vacation, everyone felt dull and apathic. He enjoyed the cheese pizza on Friday afternoons and the Perrier water during the Neuro Study Club meetings.

He gave us perspective on Neuroradiology, describing conditions in French and translating for those of us who didn't understand – for eg – Foix-a-la-jeunine and talking about his friends like Romeo Ethier, Villemure and other greats. He encouraged us to take up a topic and write a small article which he got published in the Neuroimage.

I like to think that he saw me like an excited child he gave me the responsibility of collecting the brains from the Pathology tank for Tuesday morning for brain cutting sessions. He bought me coffee and would make sure I left the office before he did in the evenings.



I continued to keep in touch, often sending him invitations to come to India which he kept refusing. Everytime I wrote to him, a definite and sweet reply would come in which he would send his regards and enquire about everything and everyone. Also, being on the NeuroImage mailing list was a joy as I could see more of his work regularly.

With his passing, Neuroradiology has lost a doyen! His unselfish nature, eagerness to impart knowledge, humility to learn from his juniors and his teaching skills have made a marked impression on me and I am sure on many of the students who passed through the Radiology Department at the MNI.

Rest In Peace Dr Melancon and God Bless your Soul.

Sunithi

Dr Sunithi Mani,  
Professor of Radiology,  
Christian Medical College Vellore. 632004



# DENIS MELANÇON - MY MENTOR

---

## Karel ter Brugge MD FRCP

Chief of Neuroradiology at the Toronto Western Hospital

I came to know Denis Melançon during my neuroradiology fellowship from 1975-1976 at “the Neuro”. He was one of 3 staff neuroradiologists at that time, together with Romeo Ethier and Garry Belanger. CT had arrived the year before in the department, being only the third such installation in the world. We were 4 neuroradiology fellows that year, Giuseppe Scotti, Stanley Tchang, Curt Milner and myself. We had a great time that year and were able to present and publish the original articles on CT imaging of Arteriovenous Malformations, Aneurysms and

Subarachnoid Hemorrhage, Gliomas and Subdural Hematomas. But what I remember the most of that year was the way Denis Melançon taught neuroradiology.

He was obviously compassionate about neuroimaging and very knowledgeable, but what stood him apart was his emphasis on the understanding of the imaging findings and how they were caused and how they could reveal the underlying pathology. This was best exemplified in his analysis of the abnormalities at the level of the sella turcica which, in those days would be mostly assessed by plain films and tomography. Denis would point out the small bony erosion of the floor of a normal sized sella indicative of an adjacent slow benign



Dr. Karel ter Brugge and Dr. Melançon in 2009  
at the Denis Melançon Lecture

process such as a small pituitary adenoma to be differentiated from an aggressive vicinity lesion creating bony destruction versus de-cortification of the normal sized sella related to global increased intracranial pressure. His search and attitude towards understanding the various neurological disorders and therefore their imaging characteristics will always be a guiding principle in my practice and I thank Denis for being such an outstanding teacher and role model.



# DENIS MELANÇON - PHOTO GALLERY

---

## François Larosée




# IN MEMORY OF DENIS MELANÇON

---

## Dr. Makki Almuntashri

Neuroradiologist at King Abdulaziz Medical city, Riyadh, Saudi Arabia



During my radiology training at McGill university (2004-2009), I worked closely with Dr. Melançon and learned a lot from him. I did my neuroradiology rotation with him at Montreal Neurological institute (MNI) and that was the inspiring time to pursue neuroradiology as my career.

Few months ago, I was saddened to learn the passing of our beloved teacher; Dr. Melançon who was always a well- respected physician, kind mentor and great teacher. All members of MNI were considering him a pillar and a leader in the neuroimaging.

The research below is my residency project that I did with Dr. Melançon which is unpublished work but it was my start in research. Now it is a memory that I want to publish in this issue of the Neuroimage to honor Dr. Melançon.

Dr. Denis Melançon; my thoughts and prayers are with you and I wish you peace.

---

## **Is the asymmetry of the temporal horns of the lateral ventricles a normal variant or is it associated with temporal lobe epilepsy?**

M.A. Almuntashri, MD; D, Melançon, MD.

Co-authors: (J. Chankowsky, MD; C.H. Torres, MD; A.K. Alhaidey, MD).

### PURPOSE

The asymmetry of the temporal horns of the lateral ventricles is often considered an indirect indicator of lateralization in patients with temporal lobe epilepsy. However, it is also a recognized normal anatomical variant. The objective of this study was to determine whether this asymmetry is more prevalent in epileptic patients.

## METHOD AND MATERIALS

After obtaining consent from the Research and Ethics Committee at our institution, two neuroradiologists reviewed the CT scans of two separate groups of patients; the control group consisting of 50 patients who presented to the hospital with history unrelated to epilepsy, and the case group consisting of 43 patients who proved to have temporal lobe epilepsy.

## RESULTS

29/50 patients (58 %) in the control group were found to have asymmetry of the temporal horns according to both observers. In the case group, the first observer found asymmetry of the temporal horns in 20 /43 (46.5 %) patients and the second observer detected asymmetry in 24 /43(55.8 %) of affected patients. P values were above 0.05 according for both observers' results, indicating that the rate of asymmetry of the temporal horns was not significantly different.

## CONCLUSION

The prevalence of asymmetry of the temporal horns was found to be comparable in both the epileptic and normal cohorts, suggesting that it is a normal variant and cannot be used to indicate the affected side in patients with temporal lobe epilepsy on CT scan. Incidentally, we observed that when temporal horn asymmetry was present, the right temporal horn was usually larger than the left.

## CLINICAL RELEVANCE/APPLICATION

Asymmetry of the temporal horns of the lateral ventricles is a normal variant and cannot be used to indicate the affected side in patients with temporal lobe epilepsy.





science, H  
learn new techn  
can variables d  
I hope

you going to miss  
re losing a friend, Please find  
ce knowing that he knew he was

Sincerely,  
Jean-Paul (JP) Acco

collabora  
declare t  
truly enjo

# LETTER TO MARIE-ODILE MELANÇON

---

Jean-Paul Acco

Chère Marie-Odile,

My heart was so warmed by your thank you card that I felt compelled to write to you. My first impression of your father was how kind and generous he was, but that is just the tip of the iceberg to describe Denis. If I could sum it up to one word, I would say that he was such a fun person, because he made work fun for me. I venture to guess that anyone who collaborated with him would declare the same thing. He truly enjoyed his vocation; there was no need to ask what drew him to radiology, it fascinated him! He was such a natural element in the Neuro world and cared so much for its welfare. He was part of a group of individuals that shaped the Neuro's status in neuroscience. He was excited to learn new technology and he had an enviable curiosity that was inspiring. I hope to be that engaged and interested for the rest of my life. His final days will always be in my good memories. For I was one of the many who cared for him, who were going to miss him dearly, who were losing a friend. Please find solace, knowing that he knew he was loved.

Sincèrement,

Jean-Paul (JP) Acco

# TALES OF STEREOTAXY AND NEURONAVIGATION AT THE NEURO

---

André Olivier MD, PhD

## Introduction


As a tribute to Denis Melanson I would like to present an overview of some of the technical contributions made at the Neuro and McGill in the fields of Stereotaxy and Neuronavigation. Denis had a passion for brain imaging and high technology and was always most supportive when the time came to apply those developments to treat patients with neurosurgical diseases.

Nowadays localizing a lesion or a structure using a computer and a pointer has become an almost routine procedure. It is however the result of a slow and progressive process that has taken place over the last forty years and to which the Neuro has participated enormously. Those developments provide examples of what can be accomplished by biomedical engineers and clinicians working together under the same roof to improve surgical techniques and patient care. These advances were made possible by close collaboration with and support from members of the Neuroradiology Department namely Romeo Éthier, Denis Melanson, Gary Bélanger, Donatella Tampieri and Maria Cortes. They would not have been possible without former MNI director Bill Feindel's unfailing commitment to provide cutting edge imaging technology and without the outstanding group of biomedical engineers involved in brain imaging namely Chris Thompson, Alan Evans, Terry Peters, Bruce Pike, Ernst Meyer, Louis Collins, Labib Soualmi and Kelvin Mok. Vaclav Tipal, his son Peter Tipal, Eddie Puodziunas and Brian Hynes were master instrument makers in Montreal whose expertise was also essential.

Stereotaxy generally refers to procedures that use some form of guidance instrument to reach a cerebral target with a probe in order to record, stimulate or make a lesion usually through a burr hole and without a craniotomy. This is the approach used at the MNI over the years by Gilles Bertrand and Abbas Sadikot to treat Parkinson's Disease and other movement disorders.

Neuronavigation refers to a positioning system that uses a pointer to localize or access a cerebral structure or lesion mostly during a craniotomy. Both approaches have much in common and rely heavily on high quality imaging and guidance systems so that the difference between the two has become less and less distinct.

In 2004 Gilles Bertrand has summarized the early years of stereotaxic surgery at McGill and I encourage anyone with further interest in the topic to refer to this instructive article and the comments it generated (1).




*Fig.1 Aubrey Mussen, a McGill graduate of 1900. The inventor of the first human stereotactic apparatus*

## The Mussen Efforts

Aubrey Mussen, a McGill graduate of 1900 was probably the first to fully understand the potential of stereotactic surgery in the human (Fig.1). In 1905 and 1906 he worked at the National Hospital, Queen Square in London with Horsley and Clark who at the time were developing a stereotactic apparatus for the cat and monkey. He quickly realized that such a device had to be matched with optimal brain imaging and went on later to build a masterful stereotaxic atlas of the monkey thalamus. What is really astonishing is that he designed an apparatus for the human and had it made by the same London instrument maker who had constructed the Horsley's and Clark's device (Fig.2). Why he and not Horsley or Clark took this daring initiative is probably due to a lack of interest from Victor Horsley who at the time was the most prominent neurosurgeon in Europe. Unfortunately, after his return to North America, Mussen was unable to convince a neurosurgeon to use his apparatus either in Montreal or at John Hopkins in Baltimore where he had relocated. It was for Spiegel and Wycis of Philadelphia to develop the field and get the credit.

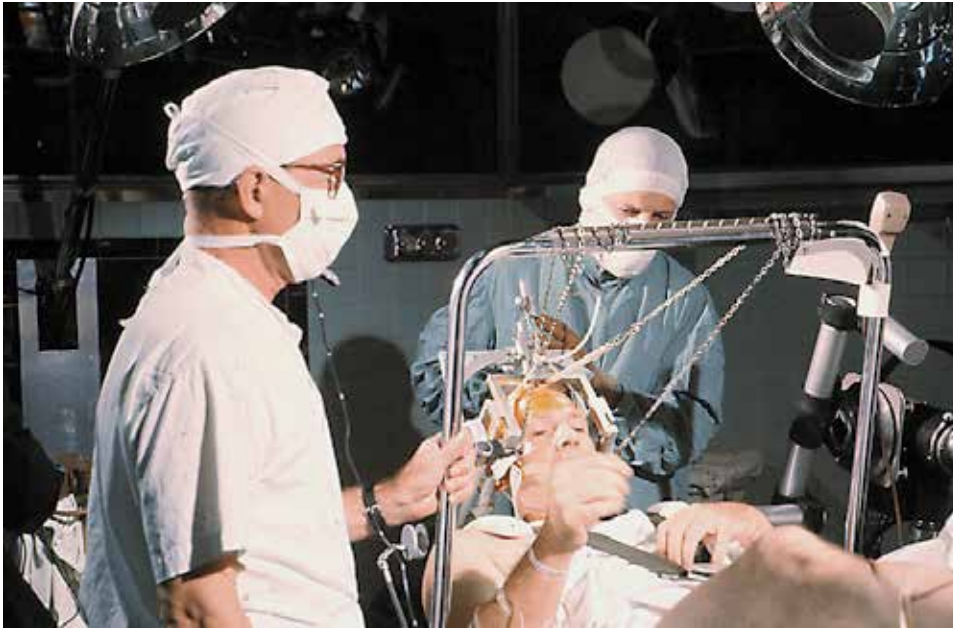
Mussen's instrument remained dormant in a barn in West Virginia, carefully wrapped with newspapers from the February 8th 1944 edition of the Washington Evening Star describing the advances of the allies south of Rome. The story of how the apparatus eventually returned to the Neuro has been narrated elsewhere (2,3). It is not clear if the human skull that was attached to the apparatus was of British, Canadian or US origin. There was no problem with customs at the borders.



*Fig.2 Mussen's apparatus built in London around 1912 and kept at the MNI*

For about 40 years Stereotaxy was based on the use of frames and ventriculography, a technique of brain imaging based on filling the brain cavities with a contrast substance. Targeting was indirect and related to internal landmarks such as the intercommisural line.

Two stereotactic systems became particularly popular. One developed by Talairach in Paris was based on Mussen's orthogonal approach and used extensively for depth electrode recording in epilepsy. Talairach's approach combined angiography and ventriculography and used very small holes in the scalp and bone to insert electrodes while avoiding blood vessels. The other system, conceived by Leksell from Sweden was based on the principle that the selected target is at the center of an imaginary sphere and that any chosen trajectory to reach it is a radius of the sphere. This was the first human apparatus used at the MNI.



*Fig.3 Thalamotomy performed by Gilles Bertrand using his own stereotactic apparatus. Late 60's*

John Blundel a McGill neurosurgeon who had done some pioneer work in Stereotaxy in Chicago with Percival Bailey joined the Neuro in 1957. Shortly after his arrival he went to Sweden as an observer and brought back a Leksell stereotaxic apparatus to the Neuro. The first stereotactic pallidotomy at the MNI was performed by Blundel and Bertrand in 1958 and the first thalamotomy by Bertrand in 1959. The original Leksell apparatus was modified in depth by Gilles Bertrand to the point that, aside from the basic principle, it

became a different and more versatile device. One striking improvement was the possibility of taking lateral x-rays to verify the position of an intracranial probe (Fig.3).


In the fifties, no doubt influenced by the ongoing work of Spiegel and Wycis and of Talairach and Bancaud, John Hunter and Herbert Jasper working at the MNI built a human apparatus that was never used probably because of its large size and the difficulty in attaching it to the head (Fig.4A).



*Fig.4A The Hunter and Jasper apparatus built at the MNI in the 50's but never used.*



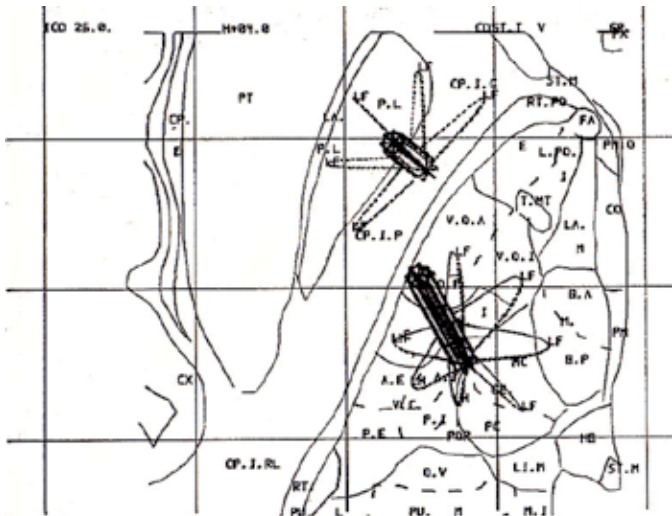
In the mid 60's the late Henry Garetson, a former neurosurgeon at the MNI developed a ball joint stereotactic device that could be screwed into a burr hole to guide a coagulating needle into aneurysms (Fig.4B). Unfortunately the induced thrombosis did not last and the procedure was abandoned.



*Fig.4B Garretson's stereotactic guide used for aneurysm coagulation (Bertrand,2004)*

## The Computer in the Operating Room

Gilles Bertrand must be credited for being the first surgeon to introduce the computer in the operating room. After visiting Expo 67 in Montreal and seeing a three dimensional rendition of a solid that could be rotated in space and examined on its various faces on a computer screen, he had the idea of applying the same principle to the thalamus and other deep brain structures to display trajectories, record physiological data and evaluate the extent of eventual lesions (Fig.5). The project became possible with the acquisition of a PDP12 computer by the MNI and the arrival of Chris Thompson, a computer engineer with the necessary expertise to write the software program (4). The computer hardware was larger than a standard refrigerator and had 16 kilobytes of live memory. (Fig. 6) The bulky computer was kept outside the operating room on a different floor but the data could be projected on a Tektronix computer graphic terminal. I had the privilege of working on the project as a fellow and my task was to manually digitalize the Schaltenbrand and Bailey's stereotactic atlas including all Hassler's thalamic nuclei. The introduction of the computer to refine neurosurgical procedures was a major landmark in the history of Functional Neurosurgery



*Fig.5 Computer map display showing the location of the probe and the extent of an eventual therapeutic lesion within thalamus. (Early 70's)*




*Fig.6 The PDP12 computer acquired by the MNI in the late 60's*

When I came on staff at the Neuro, my main interest with Stereotaxy was in the placement of recording depth electrodes for intractable epilepsy. I was aware of the work of Talairach and Bancaud in Paris and thought that we should use a similar technique to clarify seizure onset in some of the more complex cases. It turned out that the Leksell's apparatus and Bertrand's modifications were not convenient to insert the large number of electrodes required to record seizures through tiny holes as was done in Paris. With this goal in mind, we developed a double chuck stereotactic carrier mounted onto a frame and using an orthogonal approach similar to Mussen's and Talairach (Fig.7A) (5). It became the OBT apparatus (Olivier, Bertrand, Tipl) that was used for about twenty years years to insert depth electrodes. Eventually, with the indispensable expertise of Terry Peters, the frame was further modified to become the first MRI compatible stereotaxic device (Fig.7B). It was displayed at the World Federation of Neurosurgery meeting in Toronto in the summer of 1985, side by side with the Mussen apparatus (6).



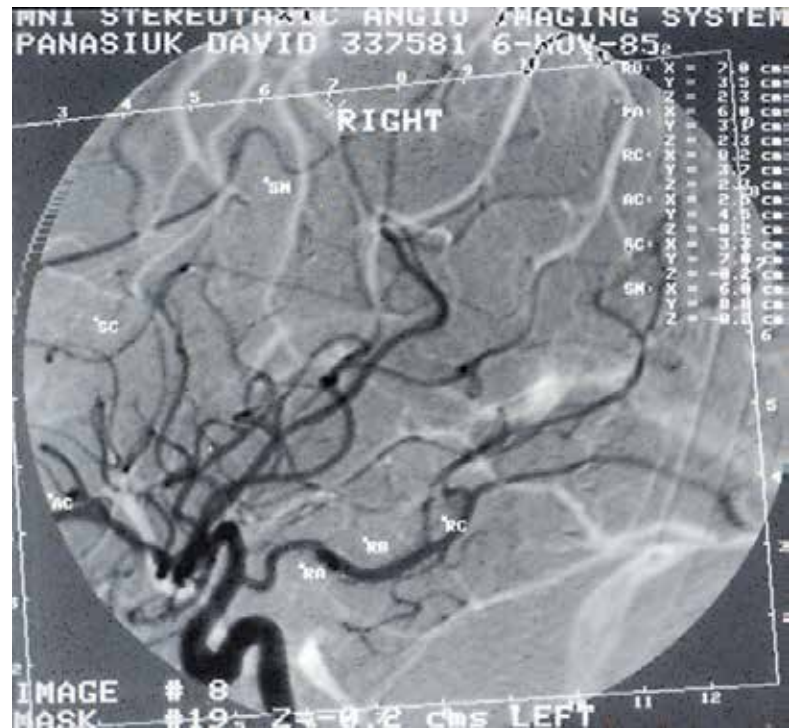*Fig.7A Orthogonal Carrier to insert depth electrodes*



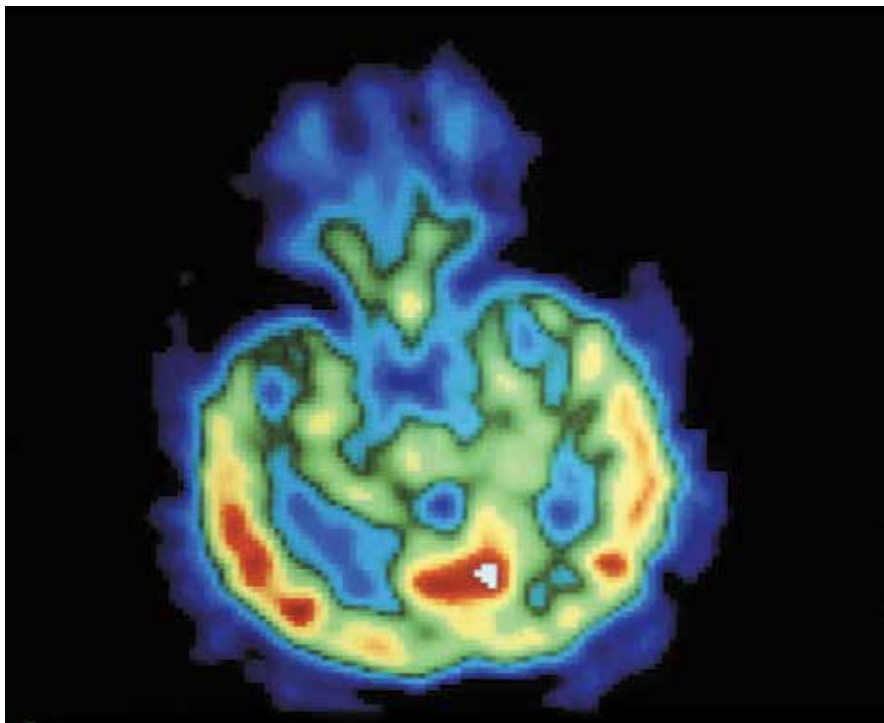
*Fig.7B MRI compatible MNI-OBT stereotactic apparatus with orthogonal carrier, 1985.*

From the very beginning, every stereotactic procedure for seizures recording was carried out percutaneously, à la Talairach, with visualization of blood vessels. Initially with the help of Denis Melanson and Gary Bélanger angiograms were performed in the operating room with the routine MNI stereoscopic views using a PUCK film changer to pick the best arterial and venous phases that were later superimposed. When the Penfield wing was built around 1978 one operating room (theater 3) was specifically made large enough to take stereotactic pictures at 4.5 meters in order to eliminate errors due to magnification and Parallax .

Like many other centers in the seventies we had adopted axial tomography for stereotactic imaging.(7) CT scanning although very useful for biopsies had striking limitations in the field of epilepsy due to its poor anatomical resolution. This limitation was compensated by the concomitant use of angiography. With the expertise of Terry Peters and his graduate student John Clark the MNI became by January 1984 the first center to use digital angiography in Stereotaxy (Fig. 8- 9c) (8).

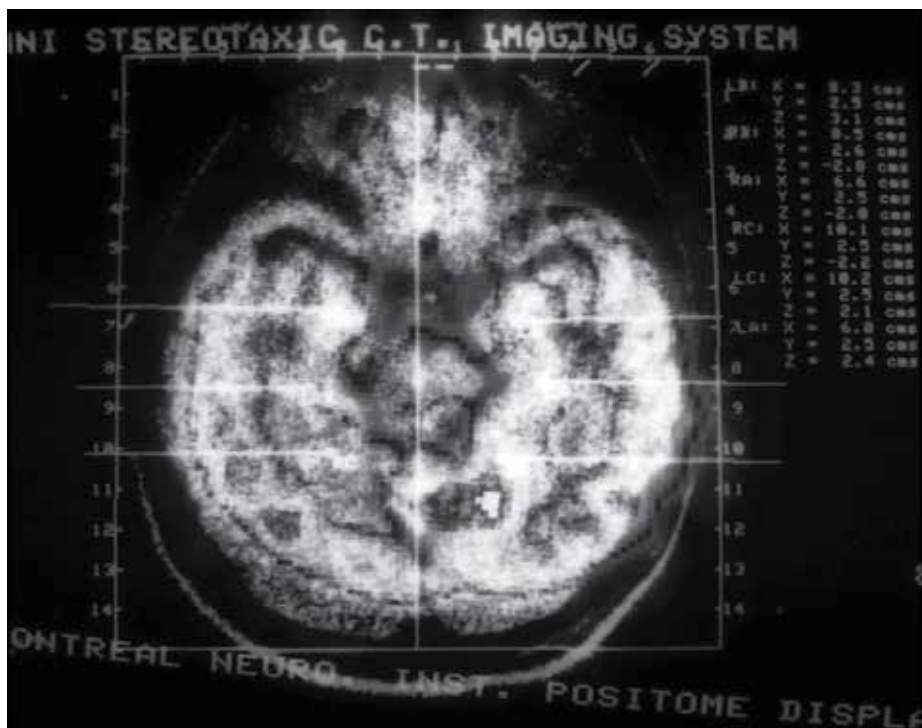

*Fig.8 Arteriovenous stereotactic digital angiography, initiated at MNI in early 1984*



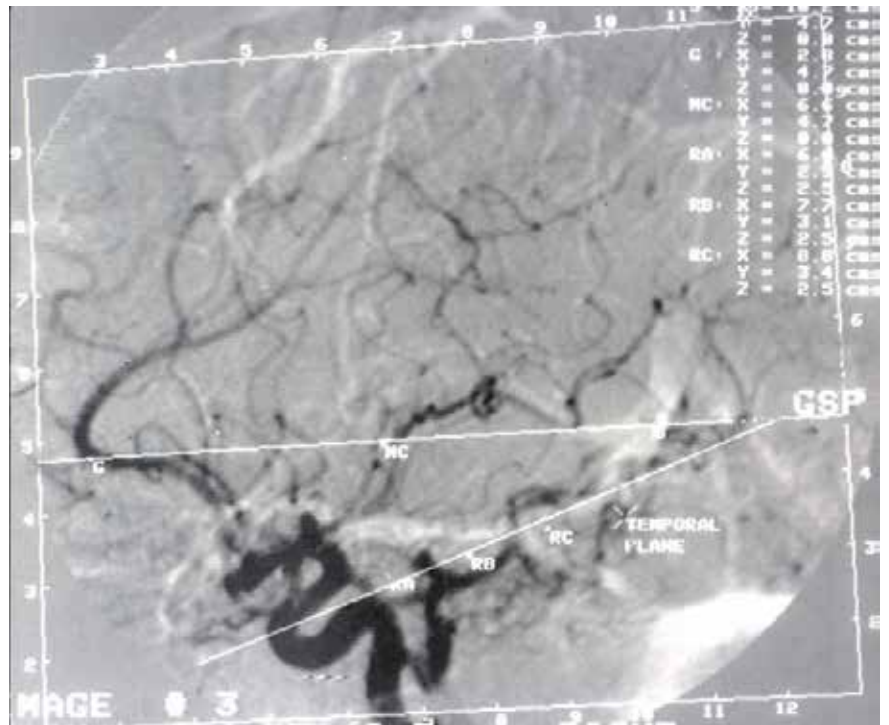
*Fig.9A PET scan in stereotaxic condition (1986).  
Refer to figs. 9B and 9C*

Using stereotaxic landmarks we were able by 1986 to integrate corresponding MRI, CT, PET and DSA images. This work was presented at the Palm Desert international meeting on epilepsy surgery in 1986 and illustrated in Engel's book. Although it was never used routinely it represents one of the first attempts to incorporate functional imaging in stereotaxy (Figs.9a-9b-9c ) (8,9).



*Fig.9.B Fusion of PET and MRI within stereotactic temporal plane with display of depth electrodes position (1986)*

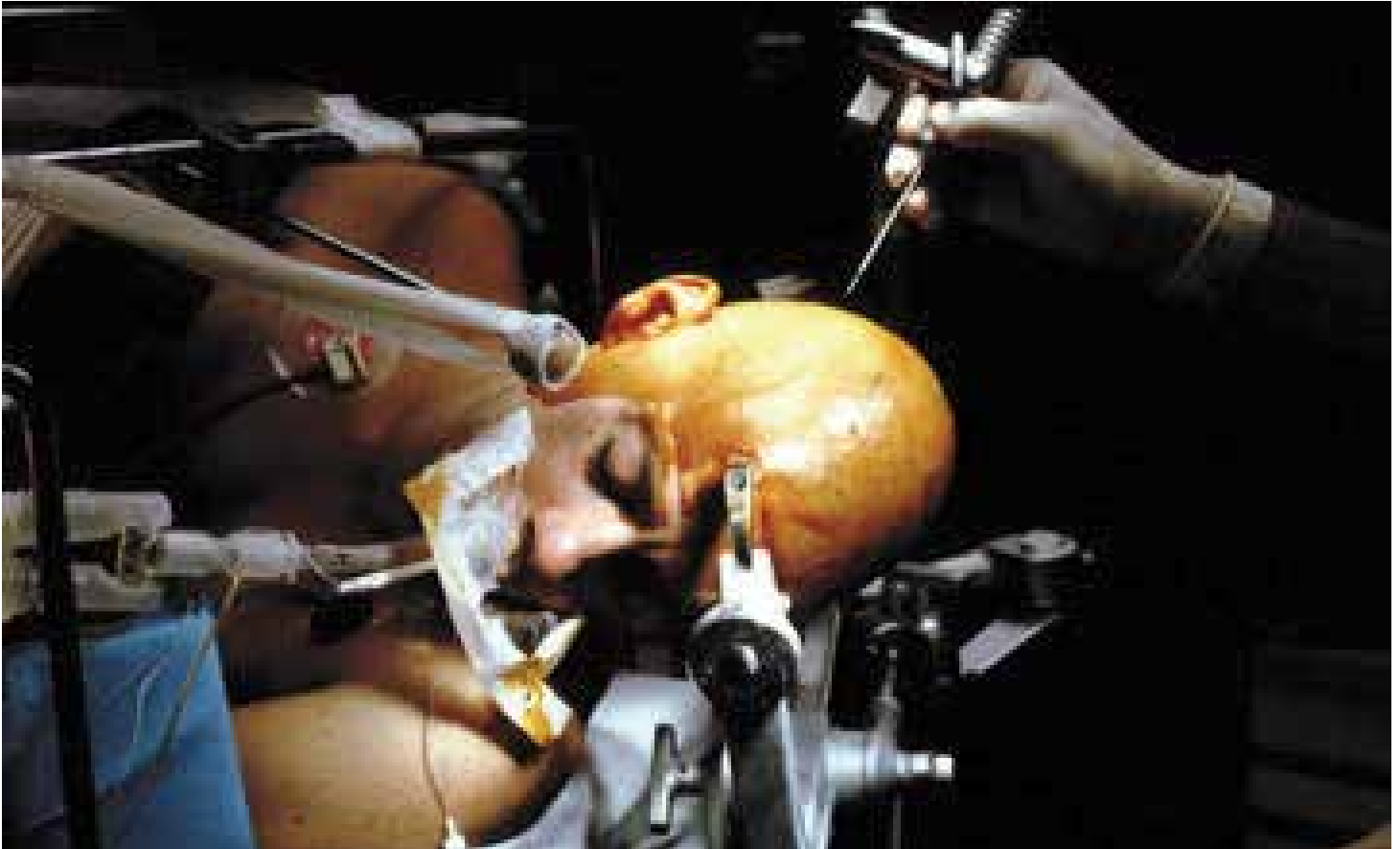
*Fig 9.C Stereotactic Digital Angiography with display temporal planes and target coordinates (1986)*



In the late 1980's, considerable efforts were made to merge Stereotaxy with Navigation by using a laser beam or a probe mounted on a stereotactic frame to perform craniotomies. Stereotaxy was merging more and more with Navigation.

## Frameless Stereotaxy

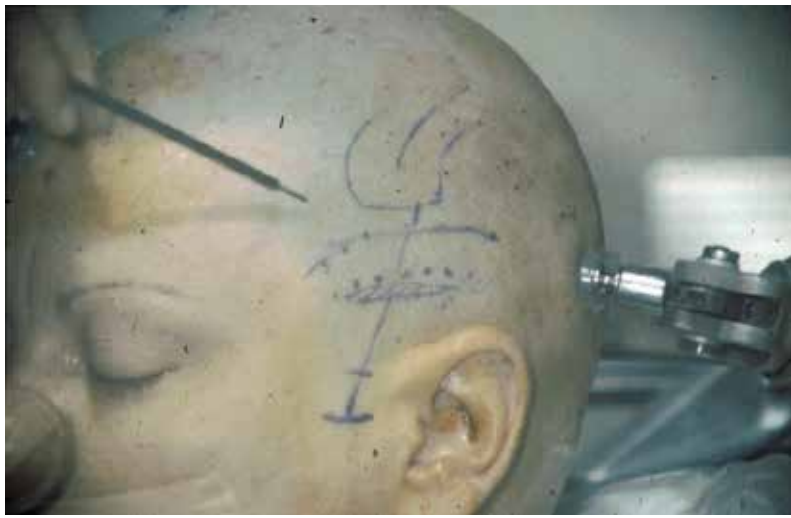
At this point in time, a major development took place with the advent of so called “Frameless Stereotaxy”. The first commercial system called the Viewing Wand was developed in the early 90’s by the ISG company from Mississauga, Ontario (Fig.10). It was acquired by the Neuro at a very good price due to a partnership with the company to obtain FDA approval. The system was essentially based on the combination of the Allegro software with the Fargo Arm.



*Fig.10 Viewing Wand. 1992. Following registration, a hand held pointer shows position of structures*

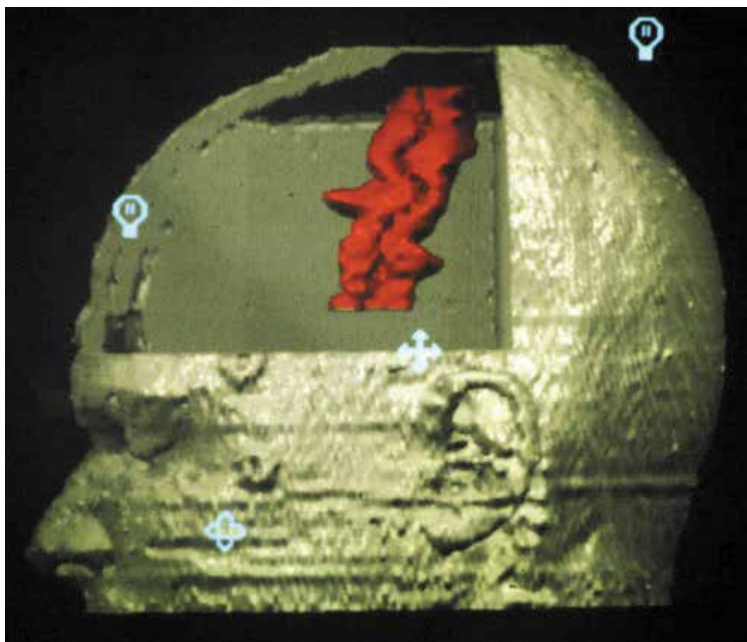
Allegro was a software program that could generate splendid 3d images of the brain. The images were impressive but not immediately applicable to standard radiology practice. (Figs 12, 13, 15) It would have had a limited impact were it not for the advent of the Fargo arm in the picture.

The Fargo arm was an articulated arm produced by a Florida company that could determine with precision the position of a point in space. The fusion of the Allegro software with the Fargo arm became the ISG Viewing Wand (Figs 10 and 11). Once registered, the system could provide two and three-dimensional display of structures, including the pointer (Figs 12 and 15). Registration, an essential step in the navigation procedure was done by matching specific points on tridimensional images of the head with the corresponding points on the patient’s real head. Following a visual accuracy check the navigation proper could go on, pointing to specific structures over the head and over or within the brain (Figs 10 and 11).



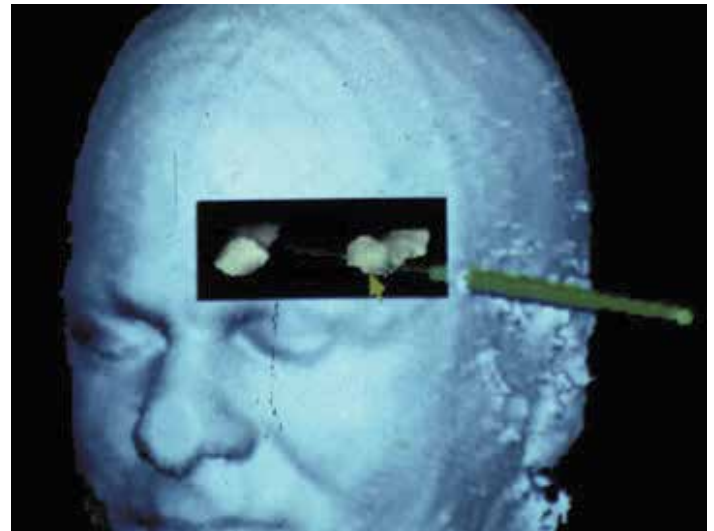
*Fig.11 Use of the Viewing Wand to plan cranial procedure. Early 90's*

With Allegro it became possible to clearly identify preoperatively the central sulcus and the sensorimotor gyri that led to better centered and smaller craniotomies(Fig.13). It also led to a new and more practical concept of cerebral localization during surgery especially when functional data generated by PET and MRI were incorporated and confirmation by stimulation could be readily obtained (Fig. 14). The usefulness of using PET for surgical guidance had already been demonstrated as early as 1992 by my colleagues



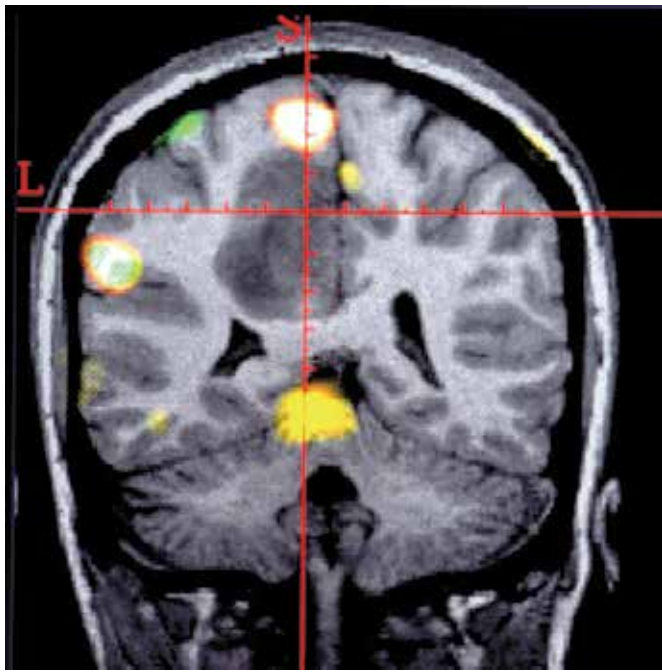
*FIG.13 Allegro software. Three dimensional reconstruction and segmentation of central area. (Pre and Post central gyri) Early 90's*

We Started using the Viewing Wand in march 1992 and readily applied it to all intracranial procedures including brain tumors and epilepsy procedures such as the transcortical amygdalo- hippocampectomy. (Fig.12) (11 ,12)

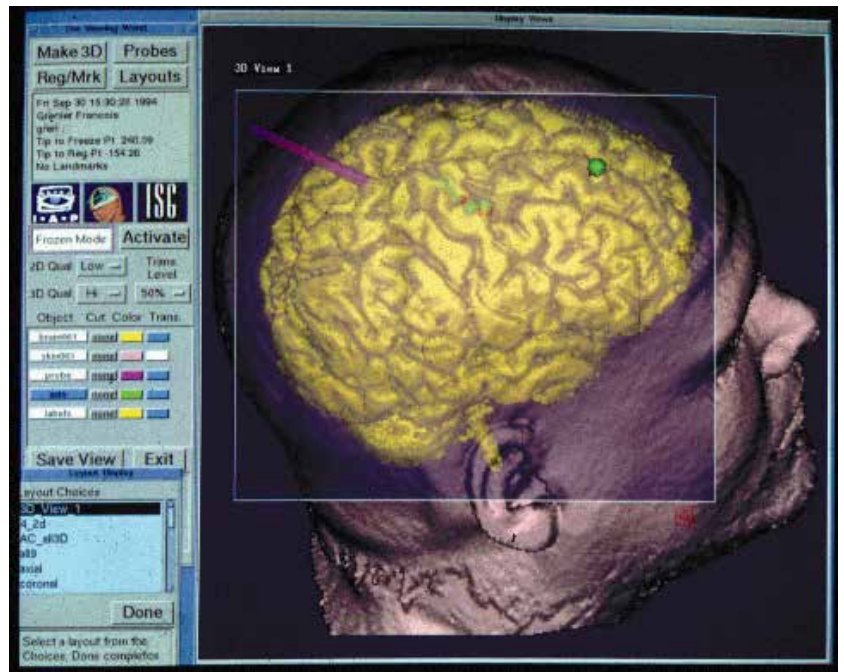


*Fig.12 Allegro 3d reconstruction and segmentation of amygdala and Hippocampus. The Viewing Wand probe is used to select a trajectory. Early 90's*

Richard Leblanc and Ernst Meyer (14). With the advent of the Viewing Wand and the tremendous help from Denise Klein incorporation of PET and MRI functional data for sensory-motor and speech mapping became a routine procedure (15).



*Fig.14 Functional Integration of PET and MRI showing location of foot, hand and face*

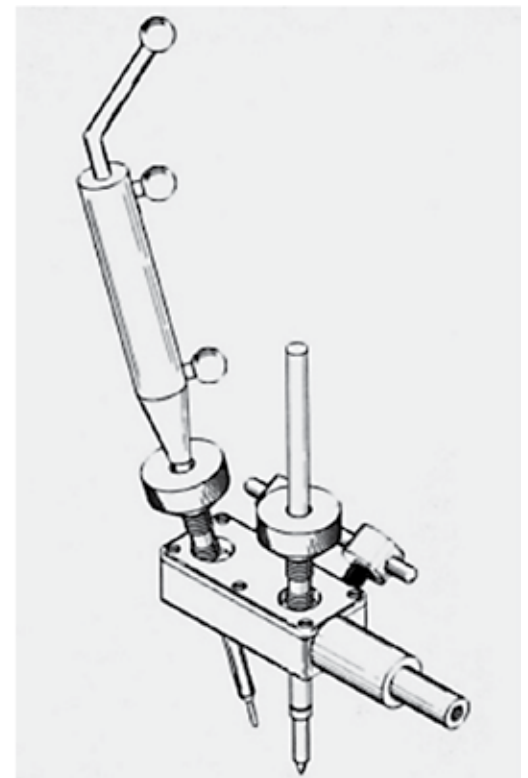


*Fig.15 Allegro 3-d reconstruction with Viewing Wand pointing to the foot area*

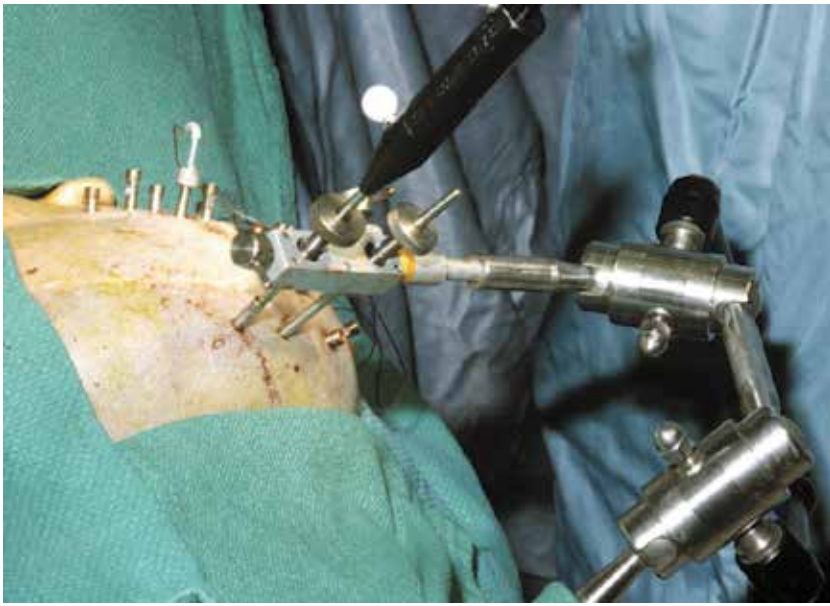
With the creation of the Navigation Unit around 1997 the use of Navigation became a more widespread routine procedure for craniotomies.

## The Free Guide

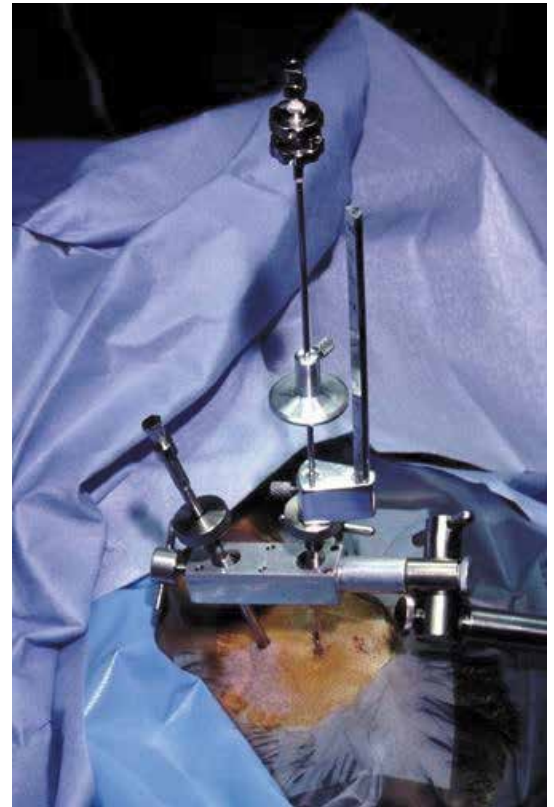
With the advent of the Viewing Wand the use of an articulated arm to reach a brain target without a frame was a logical and attractive idea. However, to actually do the procedure through the skin without incision or conventional burr holes, while maintaining the trajectory and preventing plunging or sliding represented a major obstacle. The problem was solved by developing with Brian Hynes a small compact stereotactic apparatus called the Free Guide that was essentially a double chuck device attached to an articulated arm. One chuck is used to fix a transcutaneous sharp pin into the skull to provide stability while the other chuck is used to direct a probe on target with the help of an integrated ruler after punching the skin, drilling a tiny hole through the skull and perforating the dura (Fig.16 A). Starting in 1995 and for about 15 years we have used this system to safely insert a large number of recording electrodes for epilepsy (Fig.16B) and perform percutaneous stereotactic tumor biopsies with MRI and angiographic guidance (Fig. 16C).



*Fig.16a The Free Guide. A double chuck stereotactic device for stabilization and guidance coupled to an articulated arm*




*Fig.16b Placement of intracranial depth electrodes with Frameless Stereotaxy. Trajectory defined with pointer inserted in Free Guide*



*Fig. 16c Frameless percutaneous tumor biopsy with Free guide. The right chuck skull pin provides stability and the left one is used to direct the biopsy needle on target*

## Stereotactic Radiosurgery at McGill

Starting in 1985 with Erwin Podgorsiak and Joseph Hazel a radio-oncologist at the RVH we developed the first system of radiosurgery using a linear accelerator in North America.



*Fig. 17a Modified linear accelerator gantry*

In December 1984 at a meeting of the French Neurosurgical Society in Paris, Olsvaldo Betti, a neurosurgeon from Buenos Aires presented results on obliteration of arteriovenous malformations using a linear accelerator. When I returned to Montreal I was informed by Lucas Yamamoto that McGill was renowned for its research on linear accelerators and that Erwin Podgorsak from the McGill biomedical department was among the world experts in the field. I contacted Irwin and right from the start his enthusiasm was profound and remained unaltered over the years. Many modifications had to

be made to the accelerator (Fig.17A) and to the stereotactic OBT frame in order to deliver



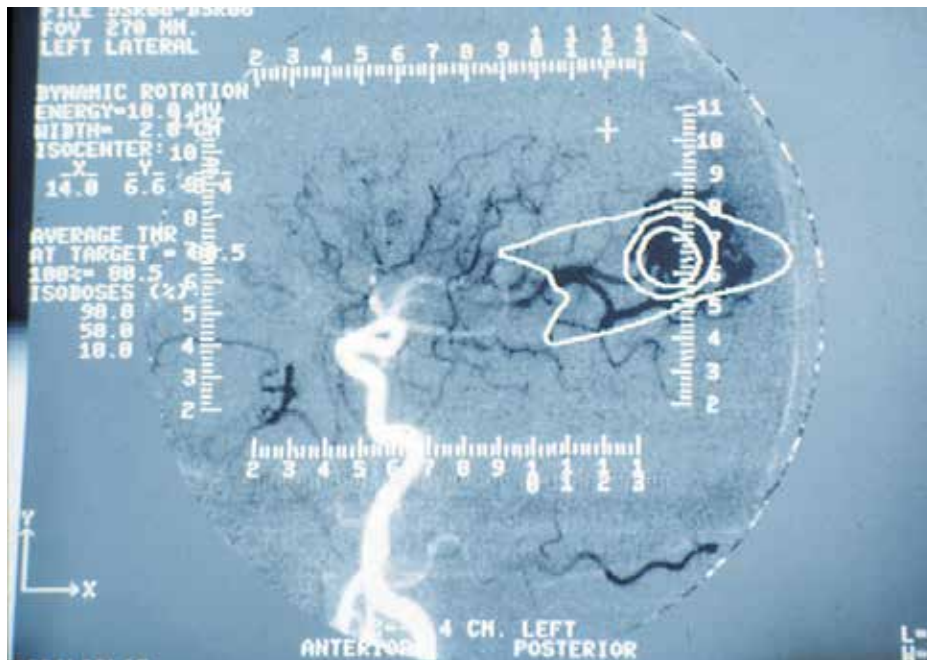
highly focused photon beam with very steep fall off of the radiation outside the target volume (Fig.17B). Erwin had the idea of using the concurrent and synchronized movement of both the gantry and the couch that became known as the McGill Dynamic Radiosurgery system (16). This mode of delivery went beyond the Gamma knife in terms of number of photon trajectories available and was the precursor to the Cyberknife that uses a robot for the delivery.

Bruce Pike and Terry Peters, two MNI engineers were the first worldwide to develop a unique three-dimensional treatment planning system for calculation of doses distribution using CT, MRI and DSA images that was eventually adopted for use with the Gamma Knife (Fig.18) (17). This sophisticated planning system was used regularly at the Neuro in the late 80's and early 90's for different types of indications. In 1986 we used it to treat a case of mesial temporal epilepsy by performing a radiosurgical stereotactic amygdalo-hippocampotomy using a 15 Gy dose delivered to the amygdala with a 10 mm beam (Fig.19).



*Fig. 17b Photon beams generated by linear accelerator*

Initial results in the treatment of arteriovenous malformations were presented at the AANS meeting in Toronto in 1988 (18,19). At about the same period we also developed a clamp that the patient kept affixed to his head while receiving fractionated focal stereotactic radiation to well circumscribed brain tumors (Fig.20)(20).



*Figs.18 Isodose display for stereotactic radiation of arteriovenous malformation.*

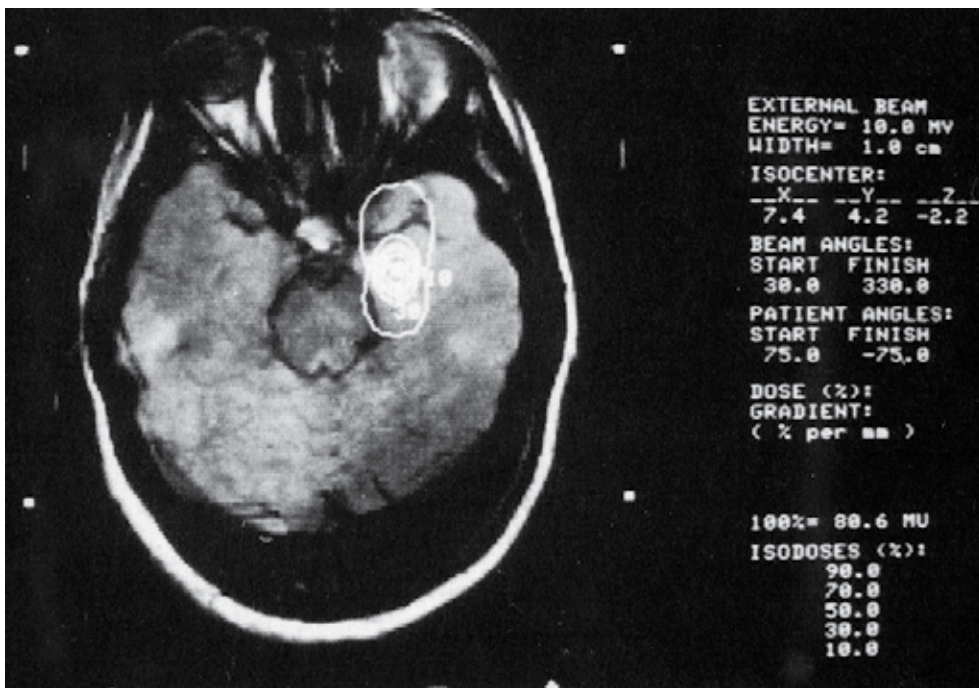


Fig.19 Isodose display for stereotactic radiosurgery of epileptic

Speaking of Gamma Knife I cannot resist narrating the unsuccessful efforts made to bring a Gamma Knife at the Neuro. In 1987 we had organized in Montreal a meeting of the American Society for Functional and Stereotaxic Neurosurgery that included a dedicated symposium on Radiosurgery. During this meeting we were approached by Dan and Larry Leksell of the Elekta company to install a Gamma Knife at the Neuro. The idea never went very far at the time because

Erwin Podgorsak was convinced that the future of radiosurgery resided in the linear accelerator. However in the subsequent years we never dared using it with very high doses and cones smaller than 7 mm as was already routinely done in many centers using the Gamma Knife.

My colleague Abbas Sadikot and I made plans to install a GK at the Neuro. Dr Roy director of professional services of the MUHC and myself met Bernard Landry premier of Quebec who told us to submit a business plan and that he would do his best to help. The plan was submitted and we were in contact all along with Mr

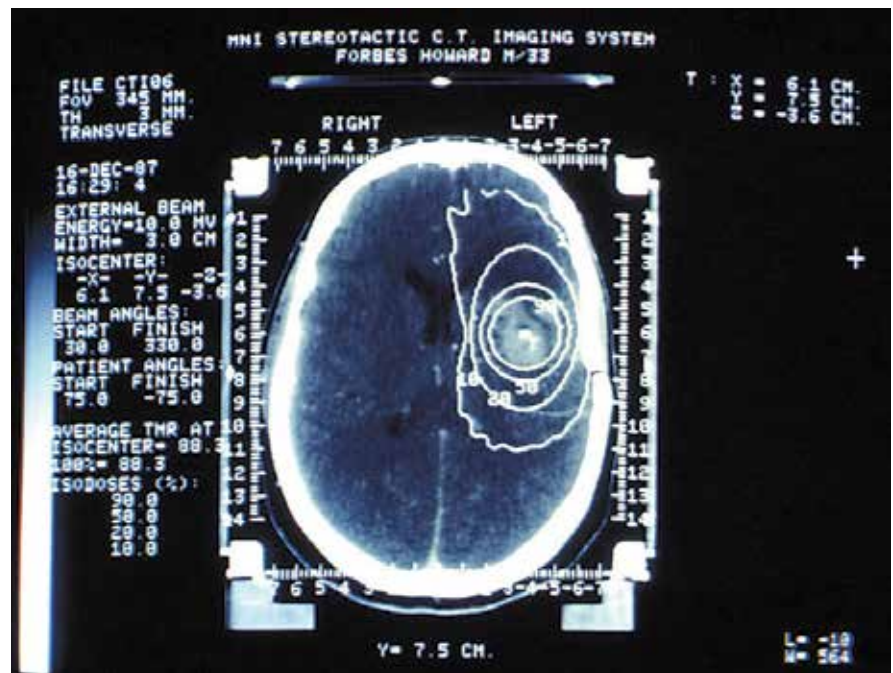


Fig. 20 Isodose display for stereotactic fractionated radiation of brain tumor. Late 80's

Francois Grenier from the ministry to follow the state of the dossier. The MNI administration was very supportive. A conference with the ministry delegates took place at the Neuro with presentations and dinner. We then learned from Mr Grenier that Dr Couillard chief of surgery at Sherbrooke had also put a request for a Gamma Knife. We were also informed that the pertinence of establishing a Gamma Knife center in Quebec was to be evaluated by l'Office des Hautes Technologies. The process took place and lasted several months. All along we were in contact with Mr Grenier thinking that our chances were high. Finally the report came out with the recommendation to establish a Gamma Knife center in Quebec.

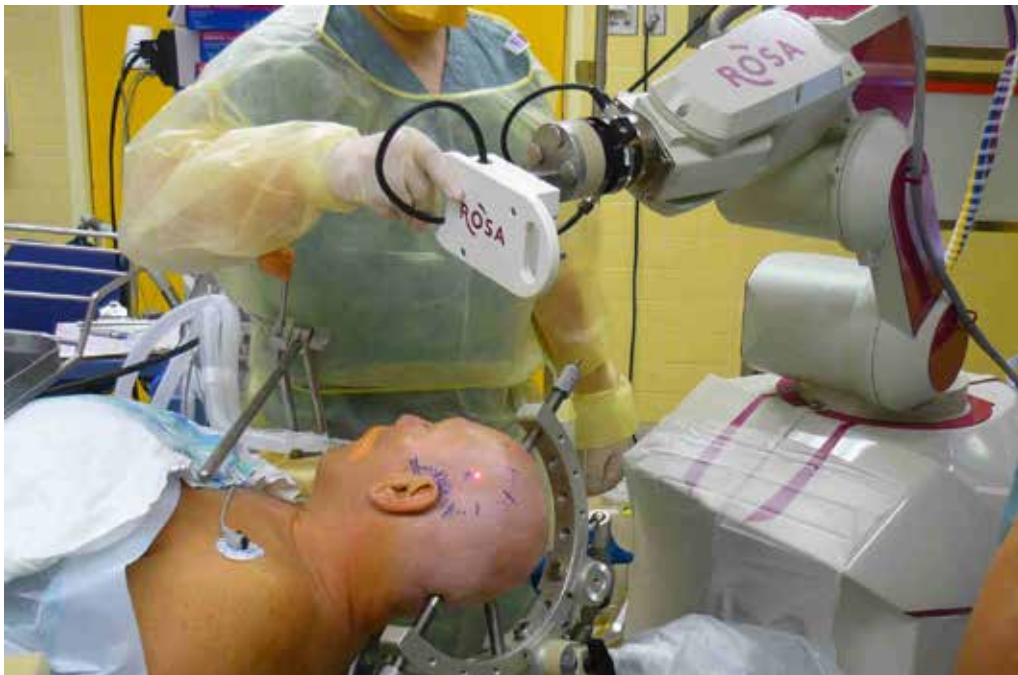In the meanwhile, the Parti Quebecois lost the provincial elections to the liberals. Dr Couillard had resigned his medical functions in Sherbrooke, had become a member of Parlement representing Sherbrooke and was appointed minister of Health and Social Affairs. Shortly afterward he announced on a late Friday afternoon that there would be a Gamma Knife in Quebec and that it would be located in Sherbrooke.

## The Advent of Rosa

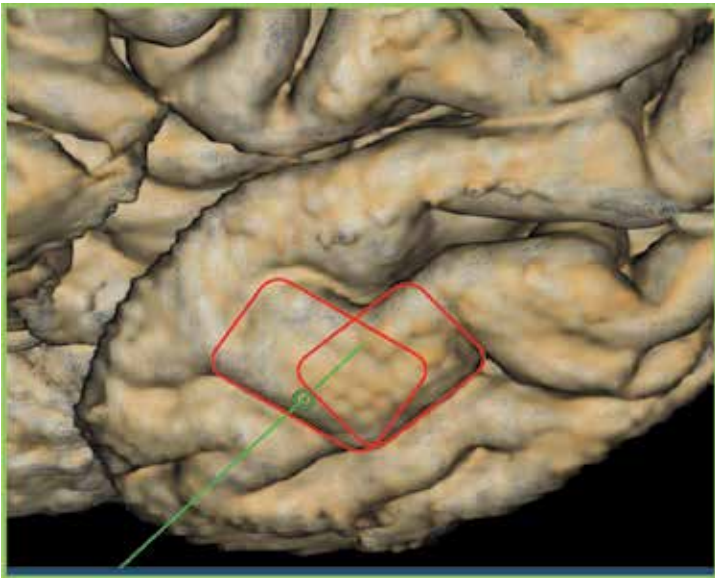
The idea of using a robot to perform stereotaxic procedures is not new and was in large part pioneered by Benamid from Grenoble. The advent of newer, more compact robots, combined with appropriate software programs made it possible to use modern brain imaging to its maximum.

In 2011 we developed a working relationship with the Medtech company from Montpellier France and started using the Rosa system for a variety of indications. Rosa stands for "Stereotactic Robot Assistance". We thought that instead of purchasing yet another standard commercial navigation system, we could get the robot and use it as a navigation system in craniotomies for epilepsy and brain tumors.

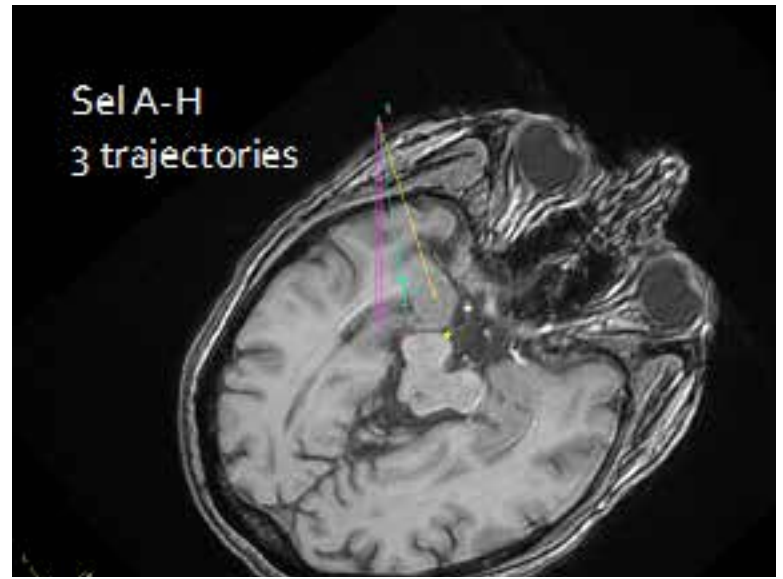
The system works along 3 modes; free, axial and isocenter-modes. In the Free Mode, a pointer can be manipulated as a navigation probe. In the Axial mode, the distance to target can be changed manually or automatically along a fixed trajectory. With the Isocenter Mode the trajectory can be altered while the target remains unchanged.



*Fig.21 Use of robot for topographic and functional guidance in craniotomies*



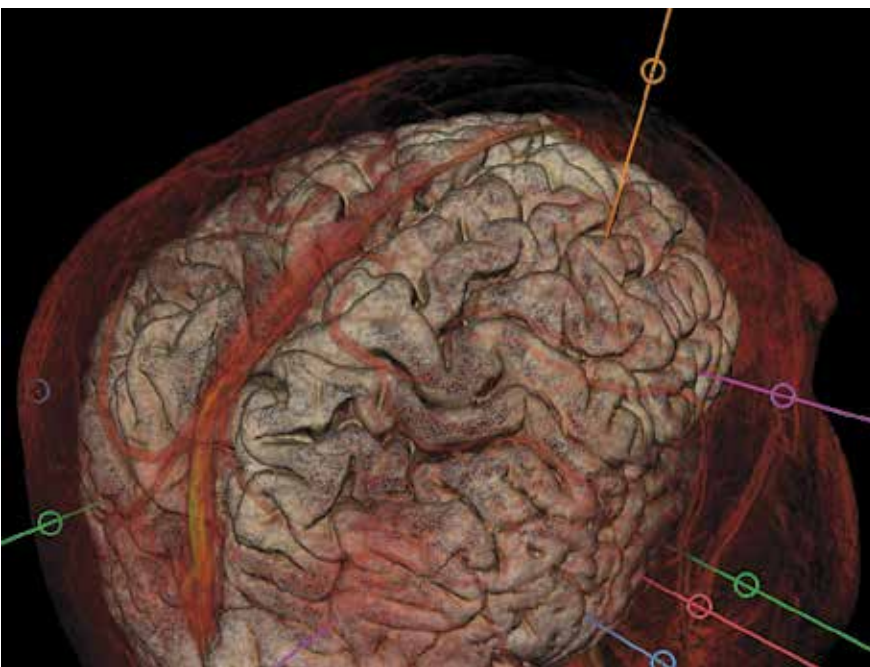
*Fig.22. A Rosa used to determine point of entry and exact position of structures and landmarks during Selective Amygdalo-hippocampectomy for temporal lobe epilepsy.*



*Fig.22.b Robotic identification of amygdala ,hippocampus and temporal horn during selective resection*

Using this software, it became easier than ever possible to fuse various modalities of imaging including CT, DSA and MRI and functional data in the preoperative planning resulting in less invasive and more precise operations. Our initial experience is based on over 200 procedures carried out over a 4 years experience. It has been used for craniotomies and for more standard stereotactic procedures such as placement of electrodes, biopsies of tumors and placement of ventricular catheter in shunting procedures. The potential of robotics in craniotomies is enormous but has for the time being a few very significant drawbacks leaving aside the financial factor. One of them is the time it takes to perform the registration and the other is the fact that the head position cannot be changed while the system is in operation. These hurdles are not insurmountable and it is likely that many of the guided neurosurgical procedures

of the future will be performed with more compact, yet sturdy robots attached to the table, allowing for unrestricted movement of the head. My colleague Jeff Hall has used the robot to insert commercial MRI compatible electrodes for epilepsy which has facilitated the work of the epileptologists.

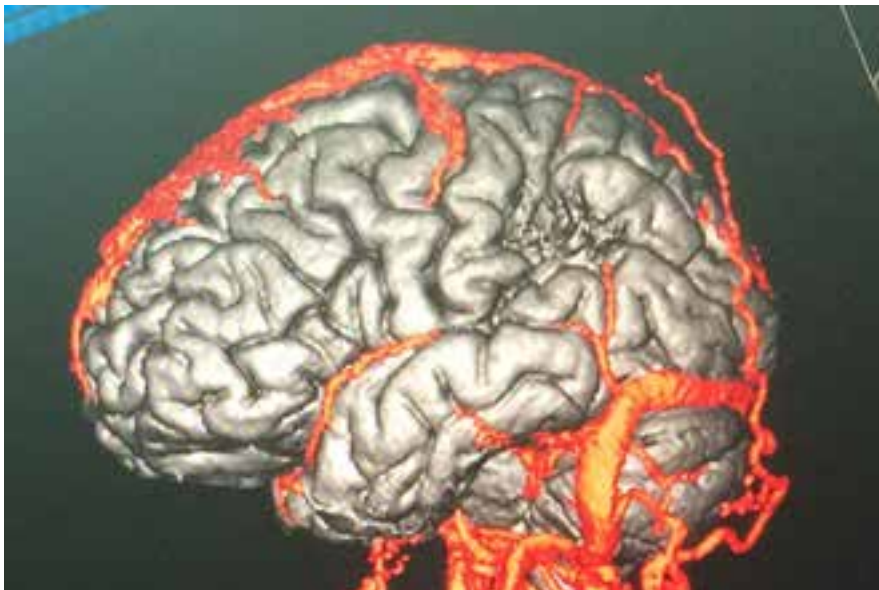


*Fig.23 Robotic approach for placement of intracranial recording electrodes in epilepsy*

## The Neuronavigation Unit

When we obtained the Viewing Wand in 1992, Arthur Cukiert, a fellow in epilepsy surgery from Brazil was able to generate high quality Allegro images for use with the Viewing Wand. Over the years other fellows including Isabelle Germano, Jorge Bizzi from Brazil and Daniel Lacerte from Quebec continued to prepare the preoperative Allegro images. Although we always had the indispensable support of the MNI basic researchers interested in image guided surgery namely Louis Collins, Terry Peters, Bruce Pike and Roch Comeau they could not be directly involved in the day to day management of patients in the operating room. Martin Cyr in 1997 was the first biomedical engineer to head the Navigation Unit. Martin was offered a position at Ste-Justine Hospital and was replaced by Lahbib Soualmi in 1998 also a biomedical engineer whose role was essential in the consolidation of the Unit. It was during his stay with us that a dedicated space on the 5th floor adjacent to the OR was allocated to the unit. The creation of the Unit resulted in all the surgeons becoming more interested and dependent on Neuronavigation. Lahbib also helped markedly in developing a working relationship with the Medtronic company that had embarked in the field of image guidance. We worked with them to develop the concept of a “Starting Operative Map”, a surgical 3D MRI-CT display of the head and brain that would contain all available topographical, vascular and functional data usable at the start of a cranial procedure. Lahbib was assisted by two technicians in Navigation, Manny Podaras and Carolynn Hurst. After Caroline’s departure, Richard Barecki took over in June 2008. Manny has now left us and has been replaced by Krikor Kalaydjian.

Kelvin Mok, another biomedical engineer who had trained with Denise Klein headed the unit after Lahbib’s departure. Kelvin’s expertise was impressive in generating high definition 3D images and fusing them with angiographic data. His role was essential in developing a highly productive working relationship with Medtech to develop the potential of ROSA by incorporating tridimensional images of the brain.



*Fig.24 3D “Starting Map” providing, for each individual patient, topographic and vascular information for Navigation onto which can be added functional data*

Since he came on staff in 1991 my colleague Abbas Sadikot has continued the tradition of stereotactic surgery for movement disorders so well established by Gilles Bertrand. He has been very successful in combining basic and clinical research. With Gilles and Louis Collins he has developed a human atlas based on MRI and has applied it to improve targeting and data collection in the rapidly developing field of Neuromodulation which he has introduced at the Neuro and which rely so much on stereotactic techniques.

## The Future of Image Guided Surgery

Looking back at some of the technological developments in Stereotaxy and Navigation at the Neuro, one is struck by the fact that these have taken place as a result of the simultaneous improvement in brain imaging and guidance systems. Maybe the best example is in the field of robotic navigation with fusion of topographic, vascular and functional data. These advances could occur because of the functional structure of the Neuro where researchers, biomedical engineers and clinicians were able to work under the same roof and shared the same interests. It is likely that this process will continue in the future and that the Neuro will remain on the forefront. Improved visualization of the cerebral cortex and subcortical structures, improved display of white matter tracts and their neurotransmitters combined to smaller, more compact and more robust robots will further expand the field of Functional Neurosurgery by allowing less and less invasive and better targeted thermoablative or neuro-modulation procedures.



*Dr. Andre Olivier, Dr. Jean Guy Villemure and Dr. Denis Melançon at the 2008 Melançon Lecture*

## References

1) **Bertrand G:**

Stereotactic Surgery at McGill: The early years  
Neurosurgery 54; 1244-1252, 2004

2) **Picard C, Olivier A, Bertrand G:**

The first human stereotaxic apparatus. The contribution of Aubrey Mussen to the field of stereotaxis. J Neurosurg. 59(4): 673-6, 1983.

3) **Olivier A, Bertrand G, Picard C:**

Discovery of the first human stereotactic instrument. Appl Neurophysiol. 46(1-4): 84-91, 1983.

4) **Bertrand G, Olivier A, Thompson CJ:**

Computer display of stereotaxic brain maps and probe tracts. Acta Neurochir (Wien) Suppl 21: 235-43, 1974

5) **Olivier A:**

Double-headed stereotaxic carrier apparatus for insertion of depth electrodes. Technical note. J Neurosurg. 65(2): 248-9, 1986.

6) **Olivier A, Peters TM, Bertrand G:**

Stereotactic system and apparatus for use with magnetic resonance imaging, computerized tomography, and digital subtraction imaging. Appl Neurophysiol. 48(1-6) 94-6, 1985.

7) **Peters TM, Olivier A, Bertrand G:**

The role of computed tomographic and digital radiographic techniques in stereotactic procedures for electrode implantation and mapping, and lesion localization. Appl. Neurophysiol. 46(1-4): 200-5, 1983.

8) **Olivier A, de Lotbinière A, Peters TM, Pike B, Ethier R, Melançon D, Bertrand G, Podgorsak EB:**

Combined use of digital subtraction angiography and MRI for radiosurgery and stereoencephalography. Appl Neurophysiol. 50(1-6): 92-9, 1987.

9) **Olivier A, Marchand E, Peters TM, Tyler J:**

Depth electrode implantation at the Montreal Neurological Institute and Hospital. IN: Surgical Treatment of the Epilepsies J Engel Jr (ed) Raven Press, New York pp 595-601, 1986.




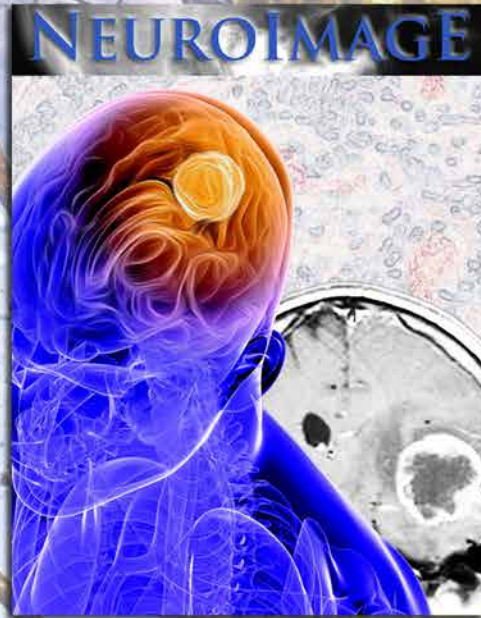


10) **Olivier A, Peters TM, Clark JA, Marchand E, Mawko G, Bertrand G, Vanier M, Ethier R, Tyler J, de Lotbinière A:**

Integration of digital angiography, magnetic resonance, x-ray computed tomography and positron emission tomography in stereotaxy. Rev Electroencephalogr Neurophysiol Clin. 17(1): 25-43, 1987.

- 11) **Olivier A, Germano I, Cukiert A, Peters TM:**  
Frameless stereotaxy for surgery of the epilepsies: preliminary experience. Technical note. *J Neurosurg* 81: 629-33, 1994.
- 12) **Olivier A, Cyr M, Comeau R, Peters T, Boling W, Klein D and Reutens D:**  
Image Guided Surgery of Epilepsy and Intrinsic Brain Tumours In Advanced Neurosurgical Navigation. E. Alexander III and R. J. Maciunas eds. Thieme Medical Publishers Inc. New York, NY 39: 469-482, 1999.
- 13) **Bittar RG, Olivier A, Sadikot AF, Andermann F, Reutens DC:**  
Cortical motor and somatosensory representation: Effect of cerebral lesions. *J. Neurosurg.* 92 (2): 242-248, 2000.
- 14) **Leblanc R, Meyer E.**  
Functional PET scanning in the treatment of AVMs: *J. Neurosurg.* 615-19, 1990
- 15) **Boling W, Olivier A, Bittar RG & Reutens D:**  
Localization of hand motor activation in Broca's pli de passage moyen. *J Neurosurg.* 91(6): 103-110, 1999.
- 16) **Podgorsak EB, Olivier A, Pla M, Lefebvre PY, Hazel J:**  
Dynamic stereotactic radiosurgery. *Int J Radiat Oncol Biol Phys.* 14(1): 115-26, 1988.
- 17) **Pike B, Peters TM, Podgorsak EB, Pla M, Olivier A, de Lotbinière A:**  
Stereotactic external beam calculations for radiosurgical treatment of brain lesions. *Appl Neurophysiol.* 50(1-6): 269-73, 1987.
- 18) **Olivier A, Sadikot A, Souhami L, Leblanc R, Hazel J, Podgorsak EB:**  
Stereotactic radiosurgery in the treatment of arteriovenous malformations with a linear accelerator. IN: *Stereotactic Radiosurgery Update*, LD Lunsford (ec) Elsevier, NY, ch 19, pp 123-128, 1992.
- 19) **Sadikot A, Olivier A, Souhami L, Bertrand G, Podgorsak EB:**  
Radiosurgical treatment of angiographically occult vascular malformations of the brain stem. IN: *Stereotactic Radiosurgery Update*, LD Lunsford (ec) Elsevier, NY, ch 30, pp 203-206, 1992.
- 20) **Olivier A, Podgorsak EB, Pla M, de Lotbinière A, Hazel J, Souhami L:**  
Stereotaxic selective fractionated radiotherapy of brain tumours- Methodology. *Can J Neurol Sci.* 16:147-8, 1989.
- 21) **Olivier A, Sadikot AF, Villemure J-G, Pokrupa R, Souhami L, Podgorsak EB, Hazel J:**  
Fractionated stereotactic radiotherapy for intracranial neoplasms. *Stereotact Funct Neurosurg.* 59(1-4): 193-8, 1992.



# NEUROIMAGE - A RETROSPECTIVE



# Peduncular Hallucino

Is a rare neurological disorder that causes vivid visual hallucinations that typically occur in dark environments, and last for several minutes. In 1922, the French neurologist Jean Lhermitte documented the case of a patient who was experiencing visual hallucinations that were suggestive of localized damage to the midbrain and pons. Lhermitte provided a full account of his work in this area in his book “Les hallucinations: clinique et physiopathologie,” which was published in Paris in 1951 by Doin publishing.

The hallucinations occurred during normal conscious state and the patient’s neurological signs were associated with those characteristic of an infarct to the midbrain and pons. Von Bogaert, Lhermitte’s colleague, named this type of hallucination “peduncular,” in reference to the cerebral peduncles, as well as to the midbrain and its surroundings.

They are normally colorful, vivid images and occur during wakefulness, and predominately at night Lilliputian hallucinations (also called Alice in Wonderland syndrome), hallucinations in which people or animals appear smaller than they would be in real life, are common in cases of peduncular hallucinosis. Most patients exhibit abnormal sleep patterns characterized by insomnia and time drowsiness

Shortly before the last Melançon lecture, I received a call from Dr. Melançon. “Have you ever heard of Peduncular Hallucinosi?” I had not. He suggested I read up on it. He would be speaking on the subject at the next lecture. He had some images forwarded to me. (right) I made some rudimentary slides, and created the image used here as a background. That was the last time we had a full conversation.

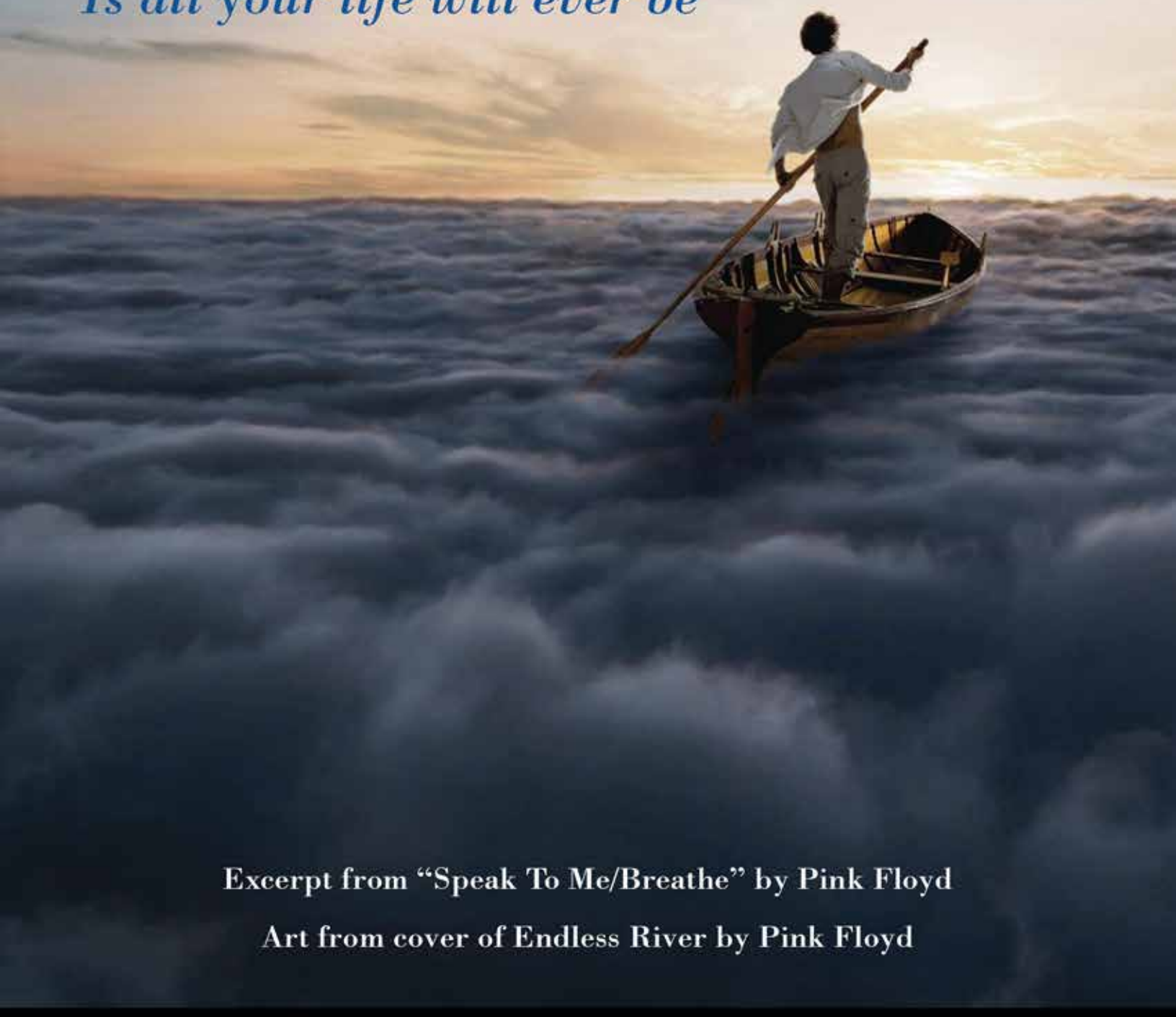
I learned afterward, he believed that he was suffering from this disorder, and hoped to document his experiences for others to learn from. He witnessed wind blowing through the plant, when there were no windows open. The water colour painting of himself moved and small animals crawled up the barometer. I certainly could not do the subject, nor his intentions justice, but I did simply want to share it, as he would have wanted.



Sis



*Long you live and high you fly  
Smiles you'll give and tears you'll cry  
All you touch and all you see  
Is all your life will ever be*



Excerpt from “Speak To Me/Breathe” by Pink Floyd

Art from cover of Endless River by Pink Floyd