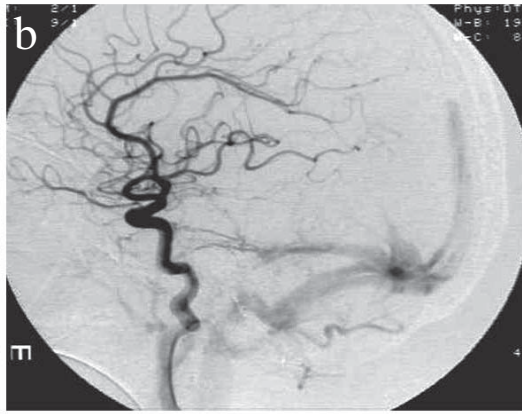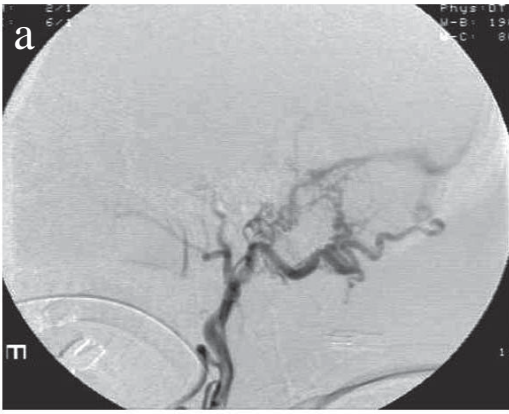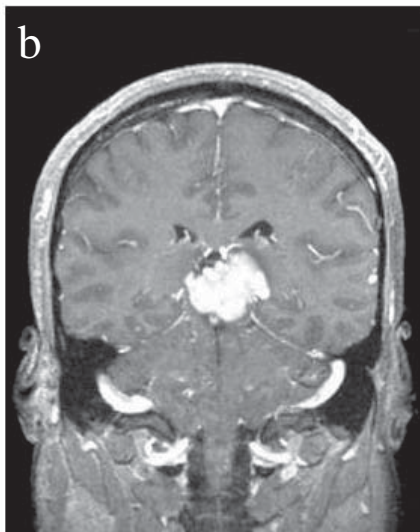
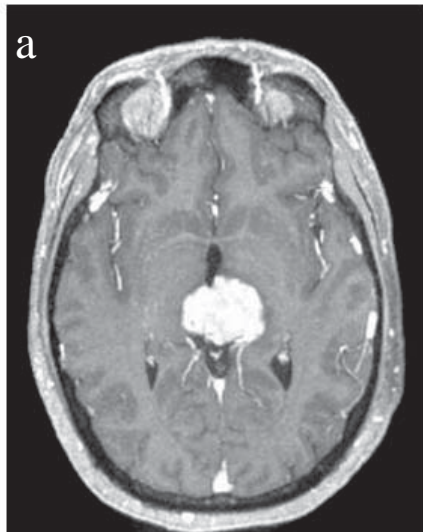
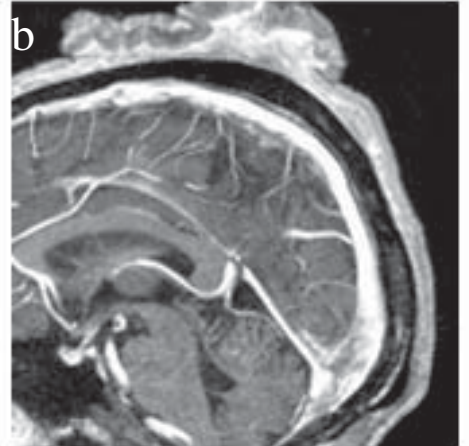
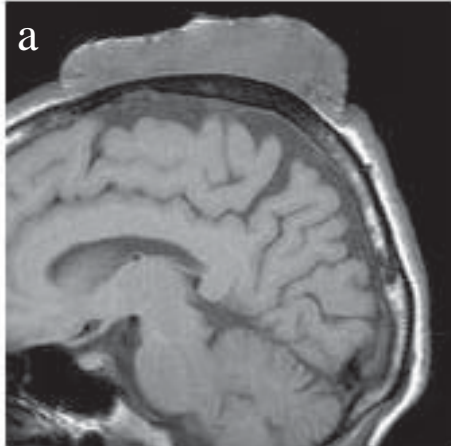


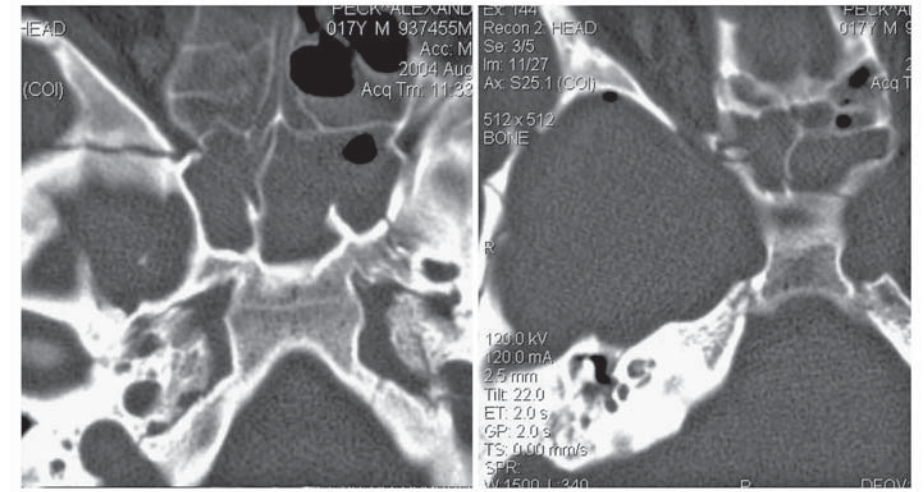
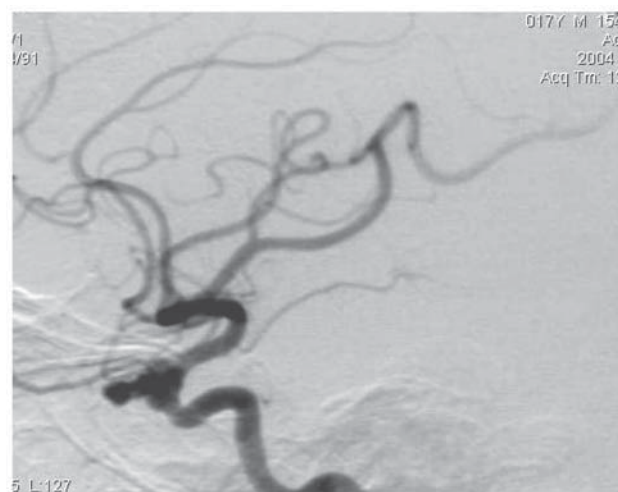Dr Linnell:  
Dural Fistula

Dr. Cortés:  
Tricoepithelioma

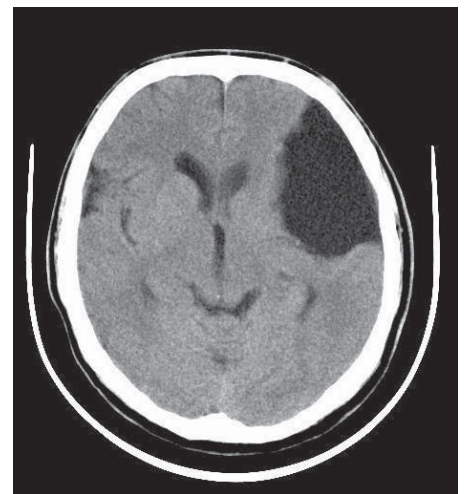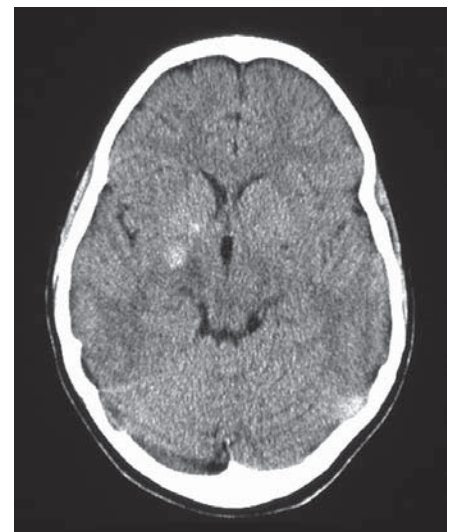
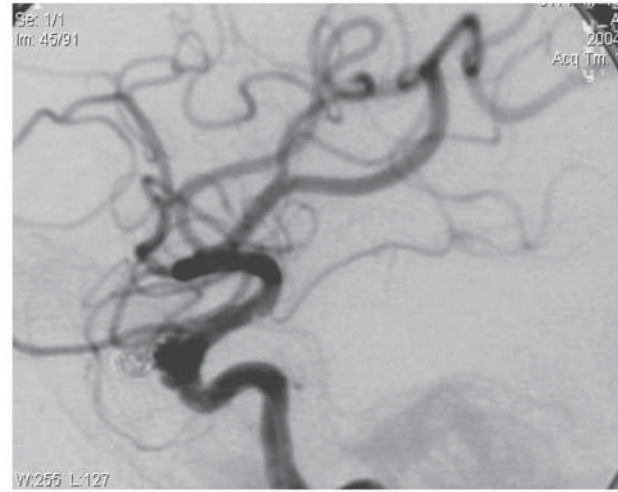


Dr. Cortés: Whipple disease

Dr. Tampieri:  
Post traumatic aneurysm



Dr. Tampieri:  
Posttraumatic aneurysm, coiled



Dr. Wee: Germinoma

Dr. Melançon:  
Arachnoid cyst

# Cases discussed at the October Study Club ..

Dr Wee – *Germinoma in basal ganglia*

Dr Guérin – *Primary central sclerosis (ALS)*


Dr Tampieri – *Post traumatic aneurysm*

Dr Chankowsky – *Suboccipital transfixion (blade)*

*Brachial plexus lesion*

Dr Linnell – *Dural fistula, and treatment*

Dr Melançon – *Epilepsy, and arachnoid cyst*

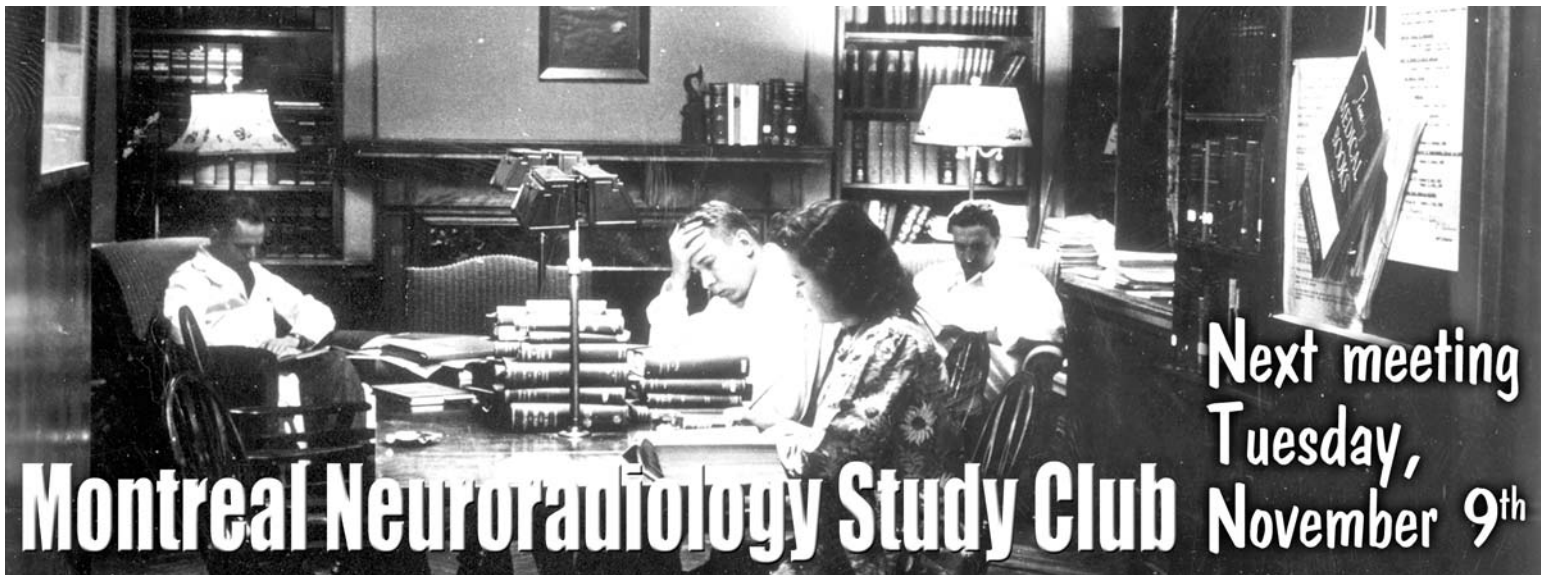


You can bring your cases on films or CD's **R.S.V.P.** by calling 398-3494 or faxing 398-7213.

email: [dmelan@hotmail.com](mailto:dmelan@hotmail.com) Also please note that the meeting now starts

in room: **Webster 201** at **6PM (18hrs)** and don't forget to sign the attendance sheet.

The meeting in Ottawa was a great success as you can see in the above snapshots taken by the official photographer Suzanne Fontaine



Next meeting  
Tuesday,  
November 9<sup>th</sup>

**Montreal Neuroradiology Study Club**