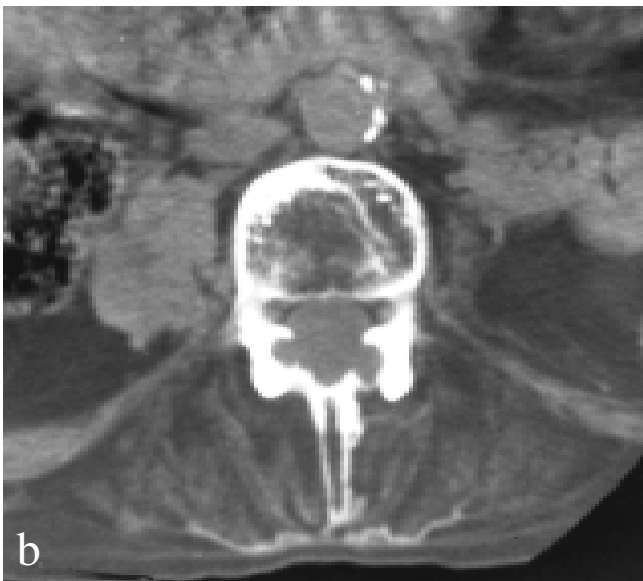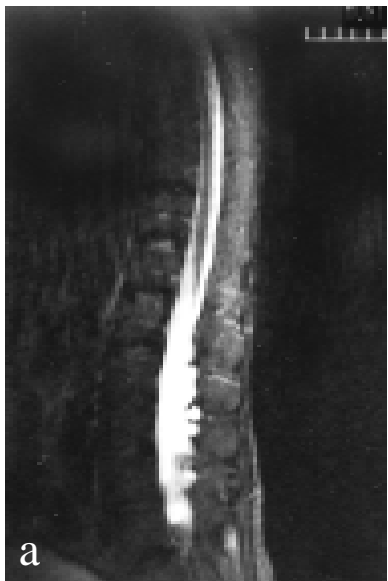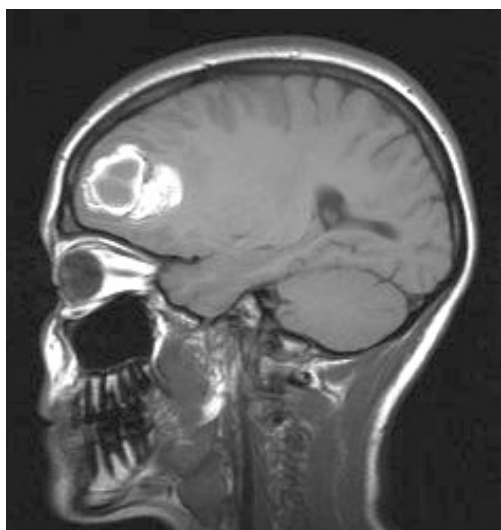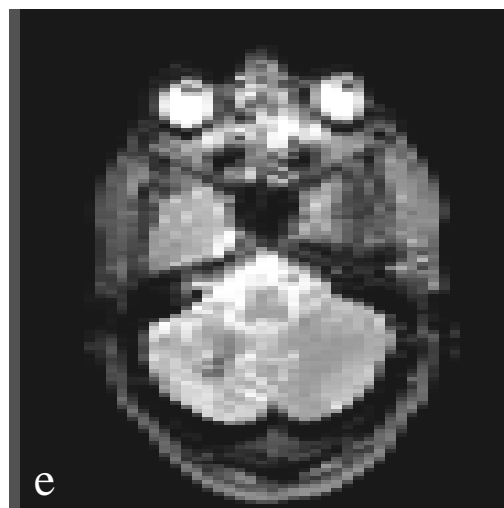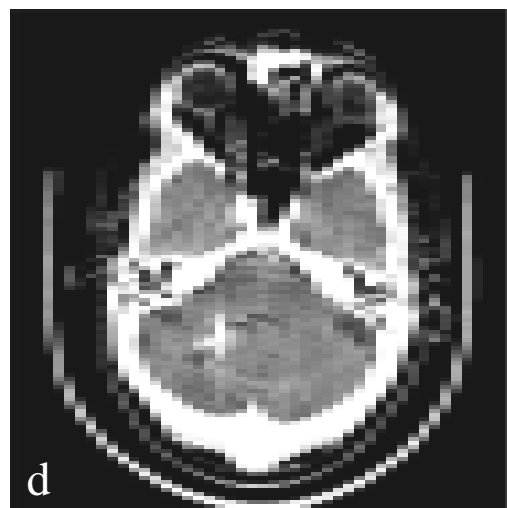
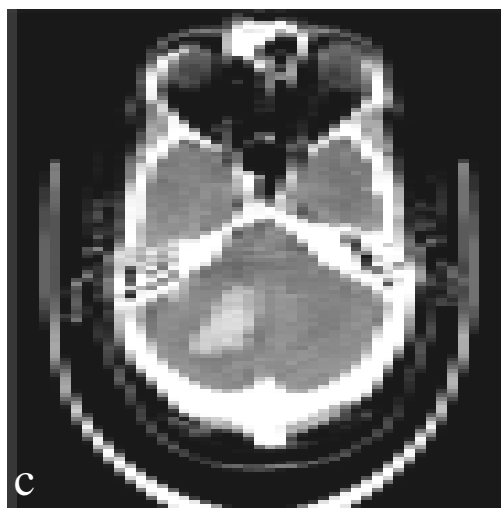
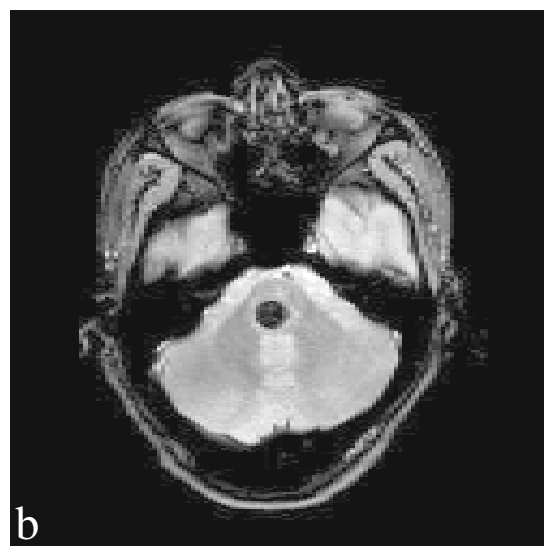
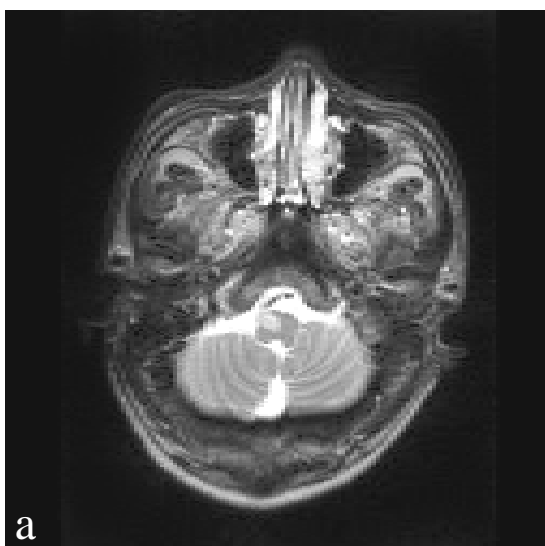


Cases discussed at the May Study Club ..



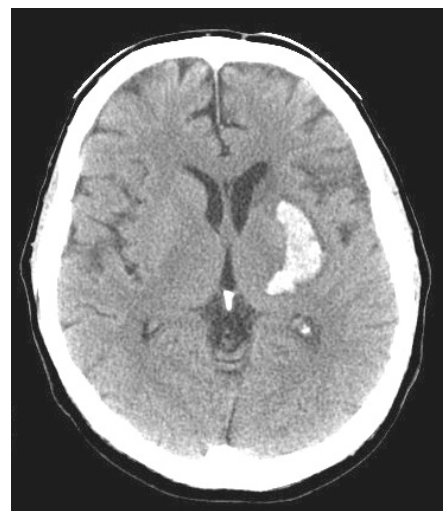◀
Dr Fontaine:
*Posterior lumbar
meningoceles in ankylosing
spondylitis*

➤
Dr Melançon:
*HOD from pontine
hemorrhagic
cavernoma: “Mollaret”
and from cerebellar
hemorrhagic cavernous-
venous*
➤



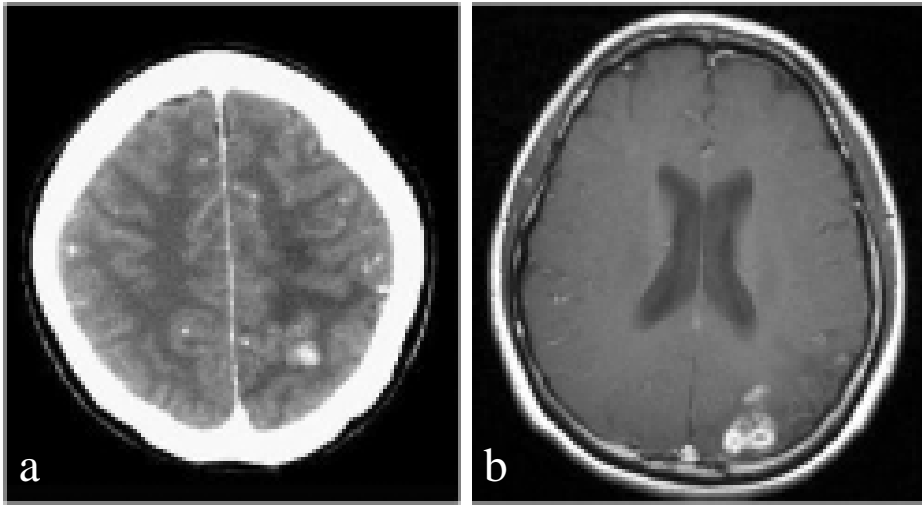
◀
Dr Chankowsky:
Frontal hemorrhage from a cavernoma

➤
Dr Chankowsky:
*Hemorrhagic infarct in left
striatum*



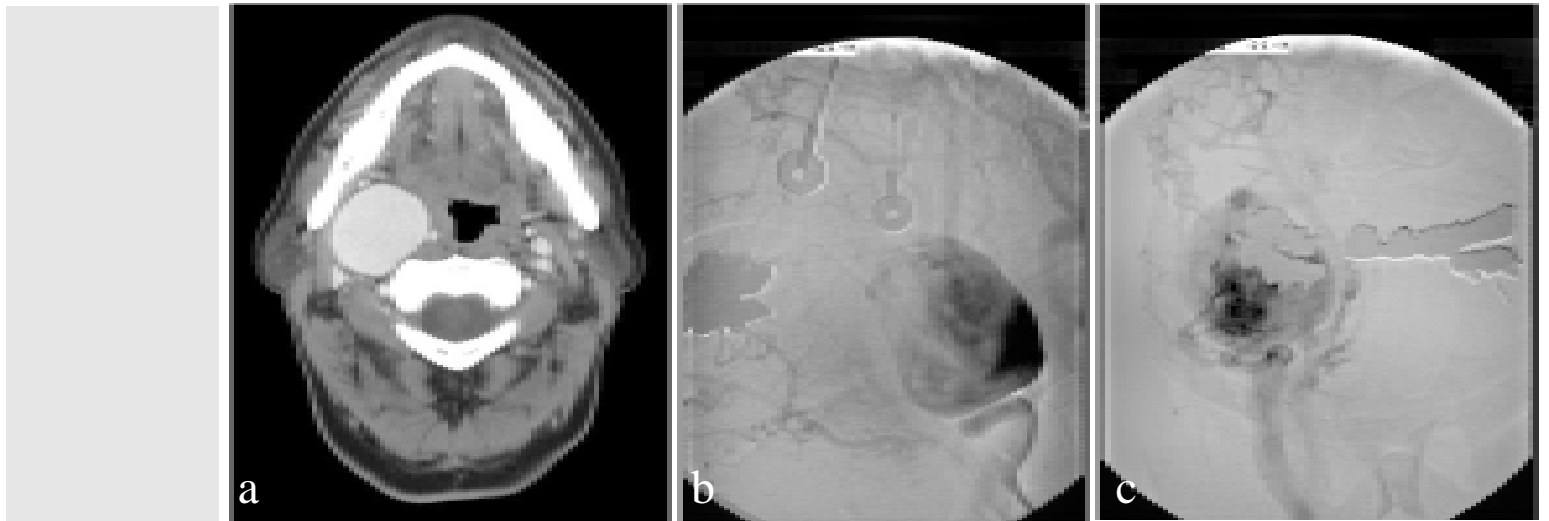
Dr O’Gorman also presented cases of *Cerebral vasculitis* and *Subdurals from prominent CSF spaces in infancy*

Cases discussed at the May Study Club ...

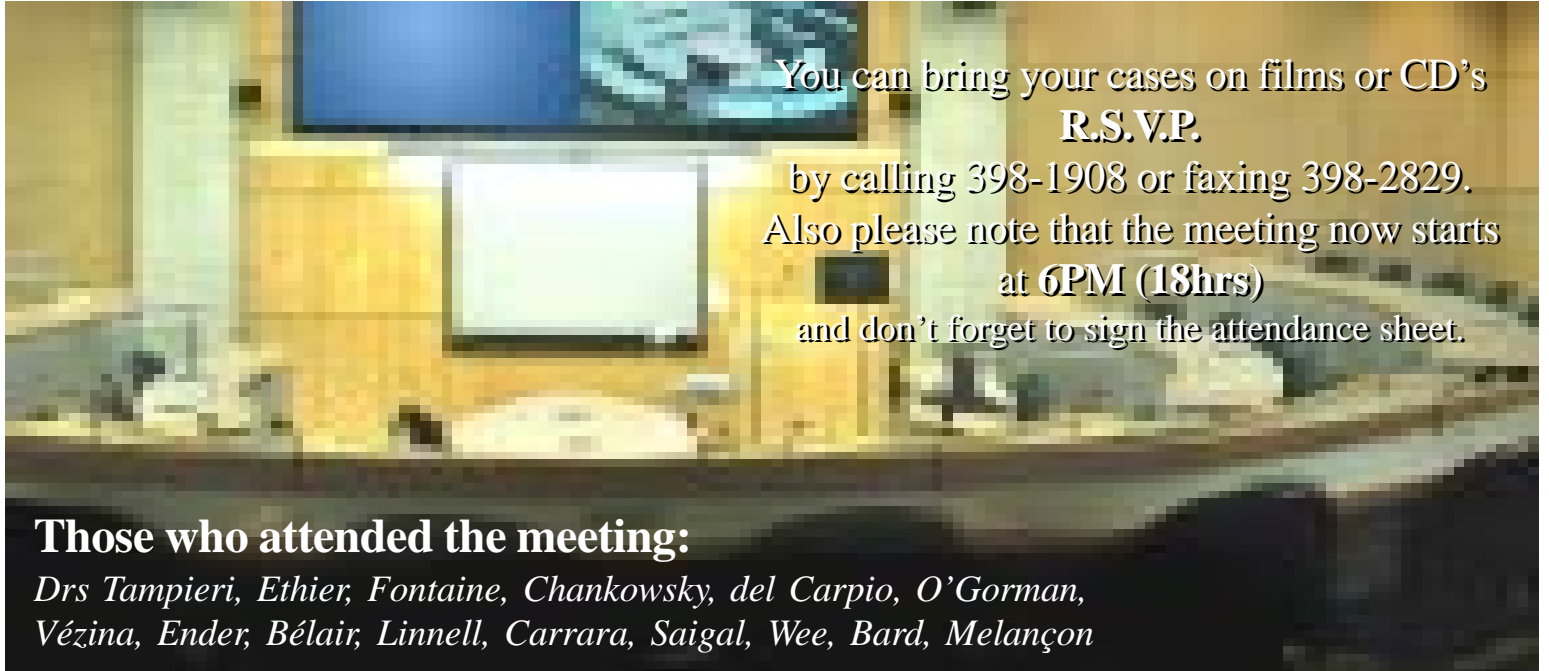


Dr. Wee:

Parasitic infestation worm nematode (Angiostrongylus cantonensis).




Dr. Tampieri: *Giant cervical aneurysm*



You can bring your cases on films or CD's
R.S.V.P.
by calling 398-1908 or faxing 398-2829.
Also please note that the meeting now starts
at **6PM (18hrs)**
and don't forget to sign the attendance sheet.

Those who attended the meeting:
Drs Tampieri, Ethier, Fontaine, Chankowsky, del Carpio, O'Gorman, Vézina, Ender, Bélair, Linnell, Carrara, Saigal, Wee, Bard, Melançon



Montreal Neuroradiology Study Club - Next meeting is Tuesday, June 8th