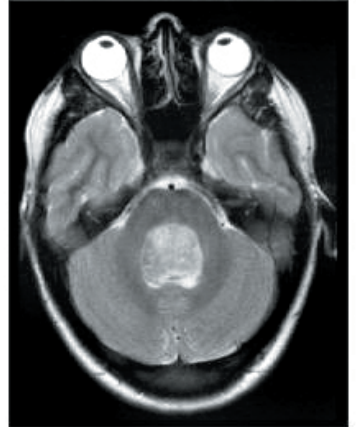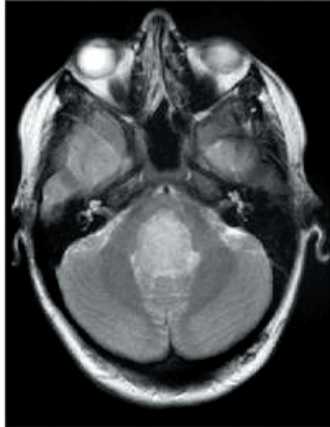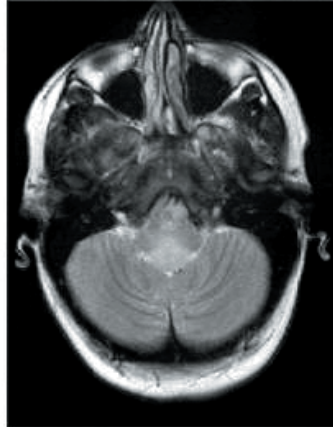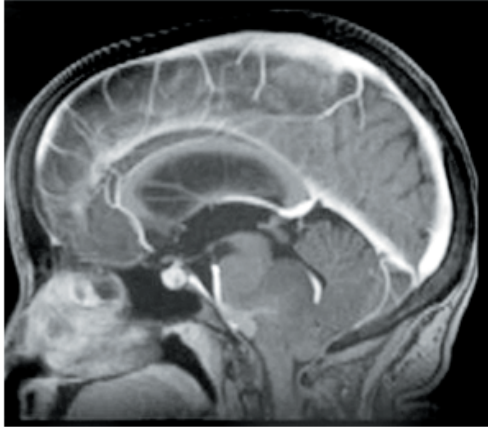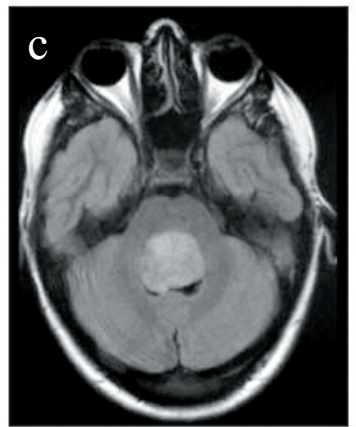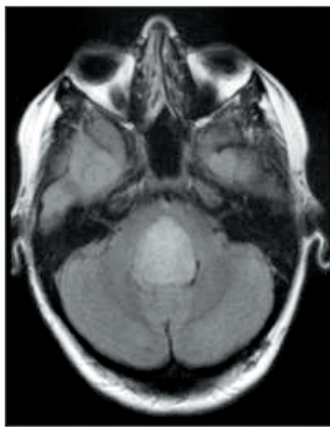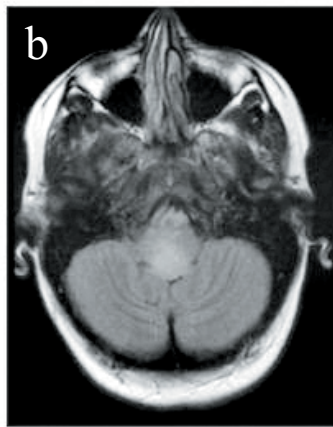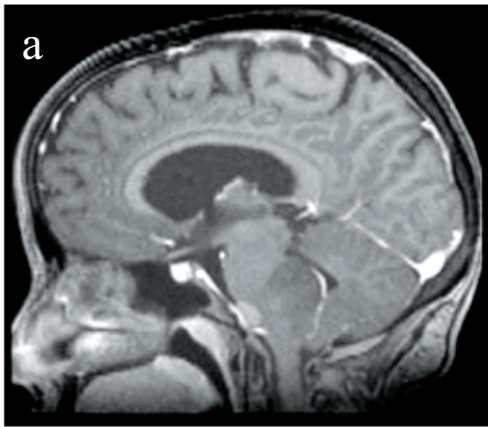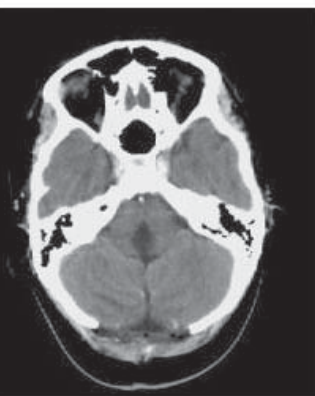
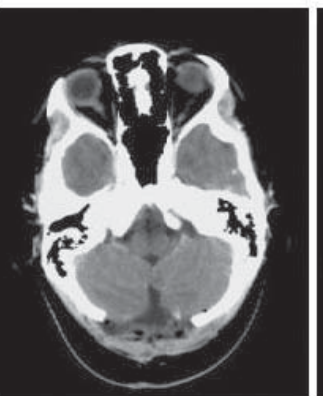
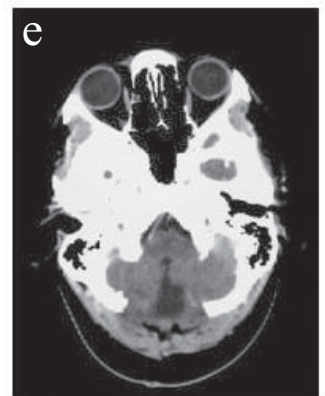
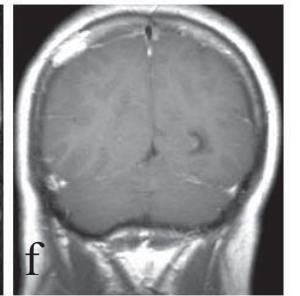
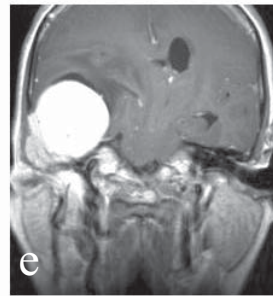
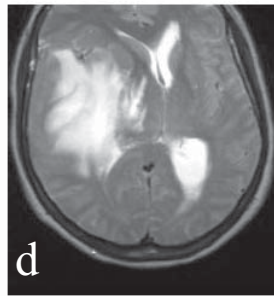
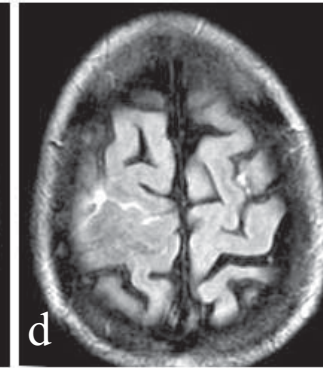
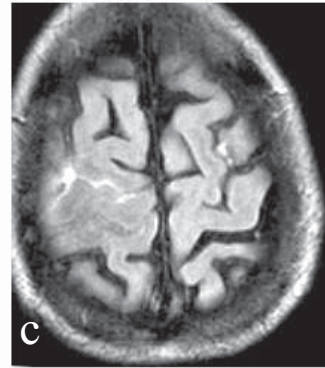
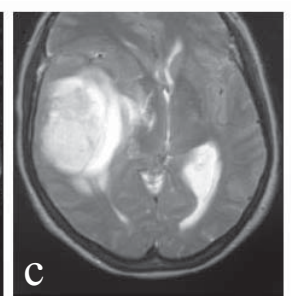
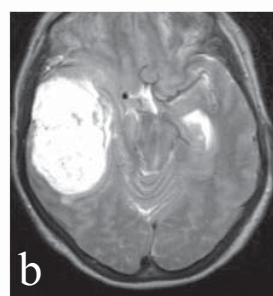
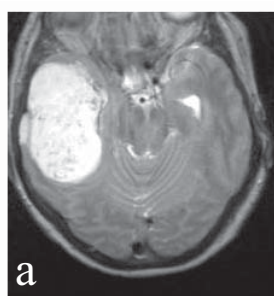
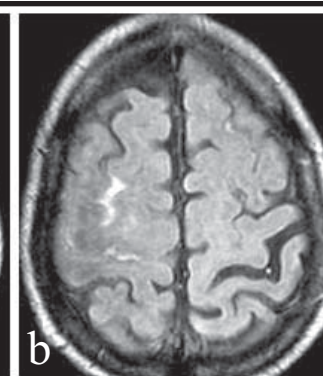
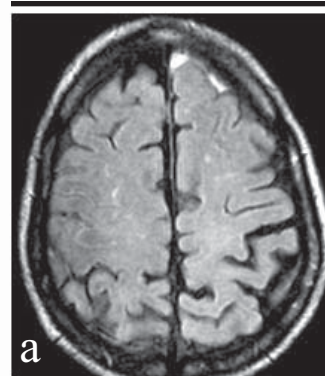


➤ **Roberto Wee:**
Epidermoid (a, b, c)
Post-operative follow-up (d, e)
Association with congenital cleft
(Journal of Computer Assisted Tomography 27(4):544-546)
 ➤

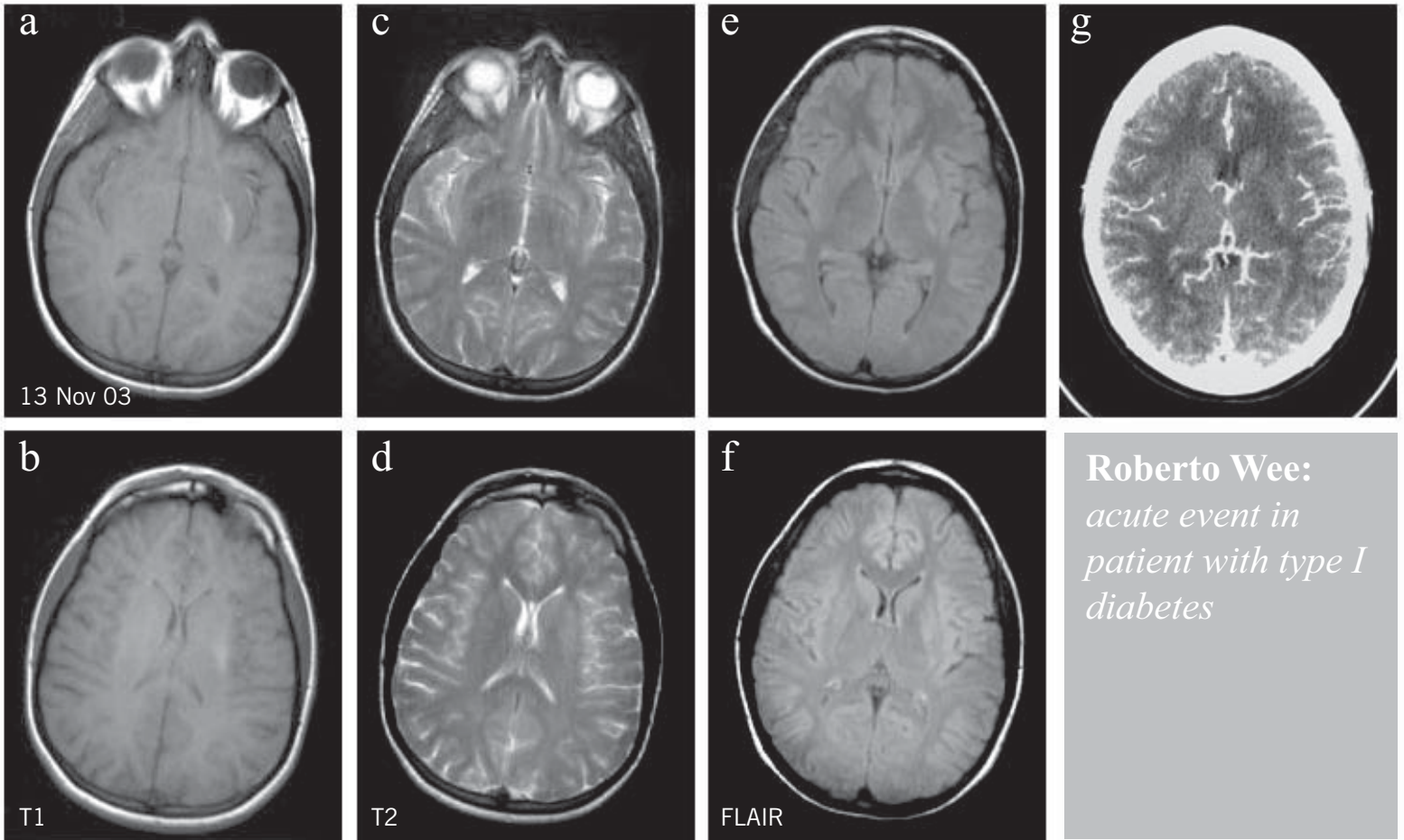


Manon Béclair: ➤
Hemangiomas



➤ **Manon Béclair:**
Amyloid angiopathy

Cases discussed at the January Study Club ...



At last month's study club, Suzanne Fontaine showed a similar case. She attributed the hyperintensity on T₁ to gemistocytes. Roberto Wee attributes it to blood and calls it vascular.

