

# Montreal Neuroradiology Study Club

Next meeting is Tuesday, February 12<sup>th</sup>

## Cases discussed at the January Study Club ...

### DR TAMPIERI

- κ *Ct perfusion pre and post carotid stenting.*

### DR BRASSARD

- κ *SAH from spinal cord AVM.*

### DR CHANKOWSKY

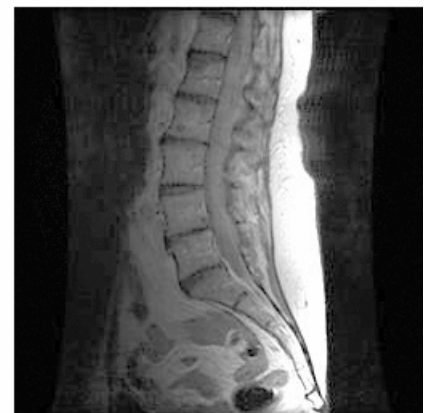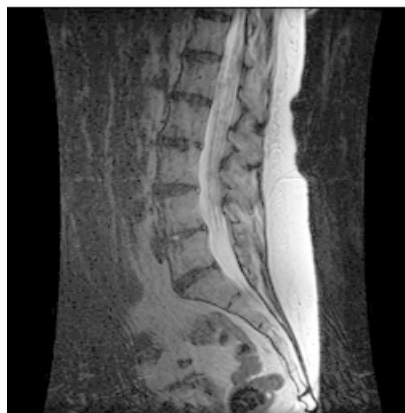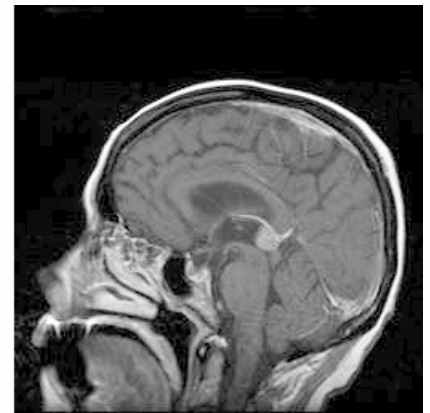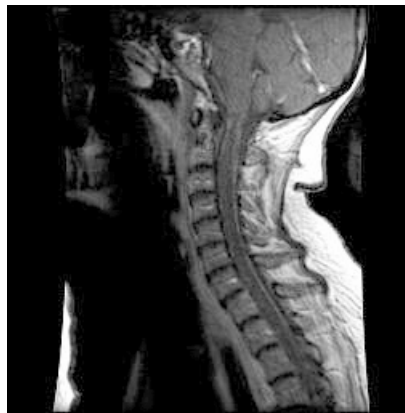- κ *Pineal lesion with extensive spinal leptomeningeal carcinomatosis. (Lung CA)*
- κ *Cavernous angioma and DVA.*
- κ *Unilateral anosmia post trauma: gyrus rectus lesion.*

### Dr O'Gorman

- κ *Right MCA infarct in 14 month old child: TB arteritis?*
- κ *Retropharyngeal phlegmon, versus abscess.*

### DR MELANÇON

- κ *2 cases of pseudo-tumoural MS.*
- κ *Right hemisphere gliomatosis.*
- κ *Left frontal tumour, hemangiopericytoma vs blastoma.*



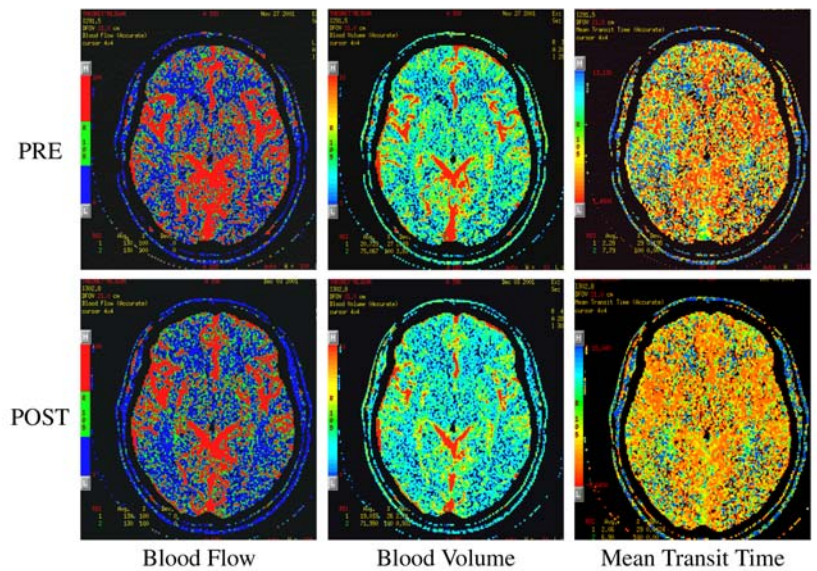
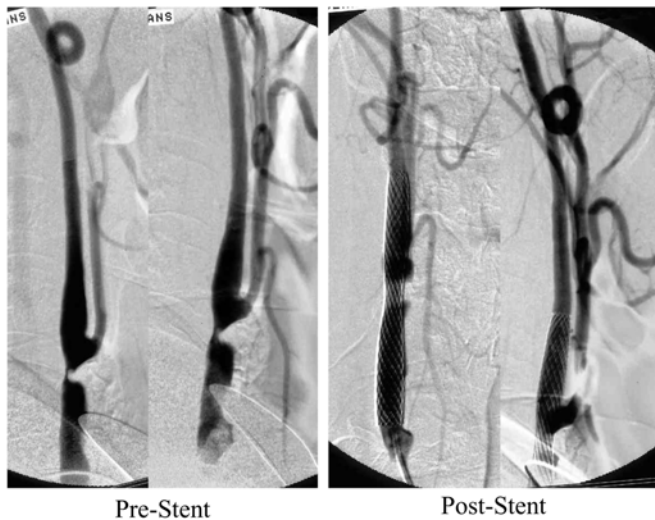### Dr. Chankowsky:

Pineal lesion with extensive spinal leptomeningeal carcinomatosis. (Lung CA)

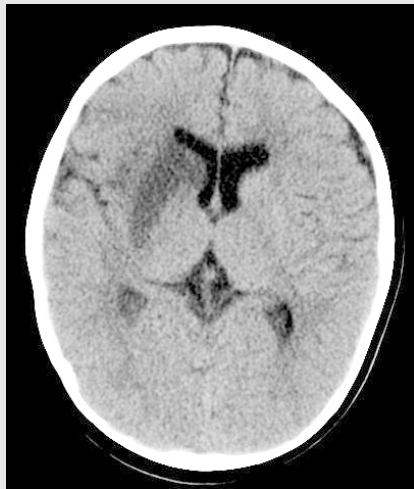## Those who attended the meeting:

Doctors: Ethier, Vezina, Tampieri, Fontaine, Gilbert, Brassard, Chankowsky, O'Gorman, Sinclair, Ender, St-Onge, Nauwelters, Denegri, Melançon.

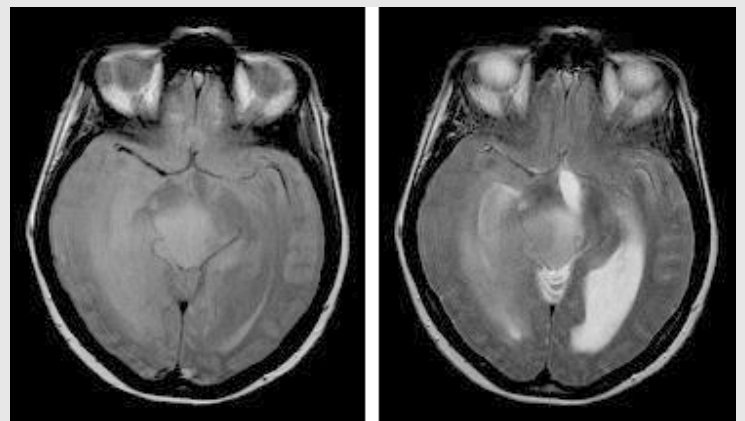
**Dr Tampieri:** Ct perfusion pre and post carotid stenting.



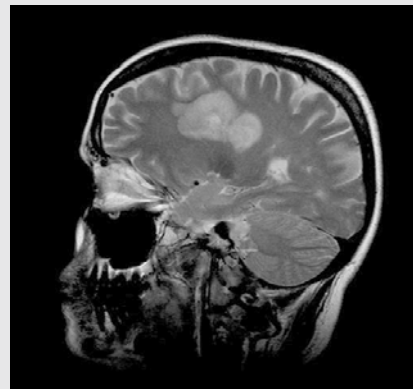February 12, the date of the next meeting, is Mardi Gras.  
Luncheon will be more stuffy and wine will be adjusted.



**Dr O’Gorman:**  
Right MCA infarct in  
14 month old child: TB arteritis?  
Discussion on striatal arteries



**Dr Melançon:** Right hemisphere gliomatosis.



**Dr Melançon:** Pseudo-tumoural MS.

**You can bring your  
cases on films or CD’s**