

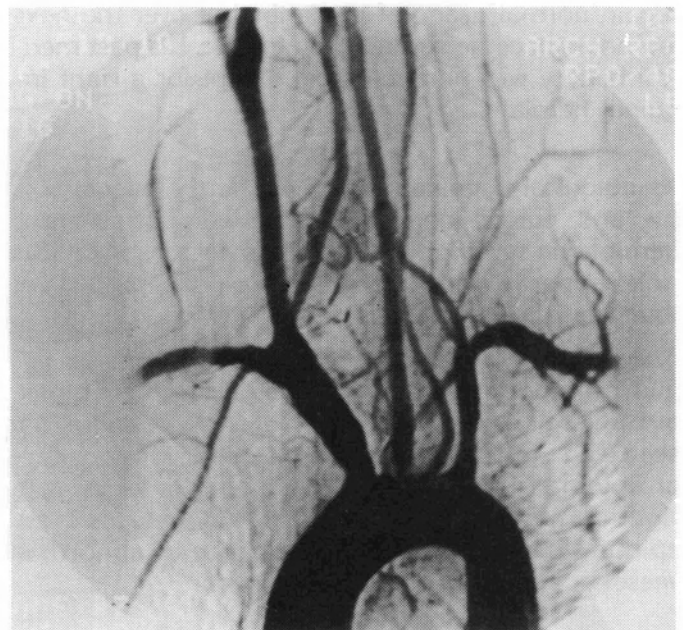
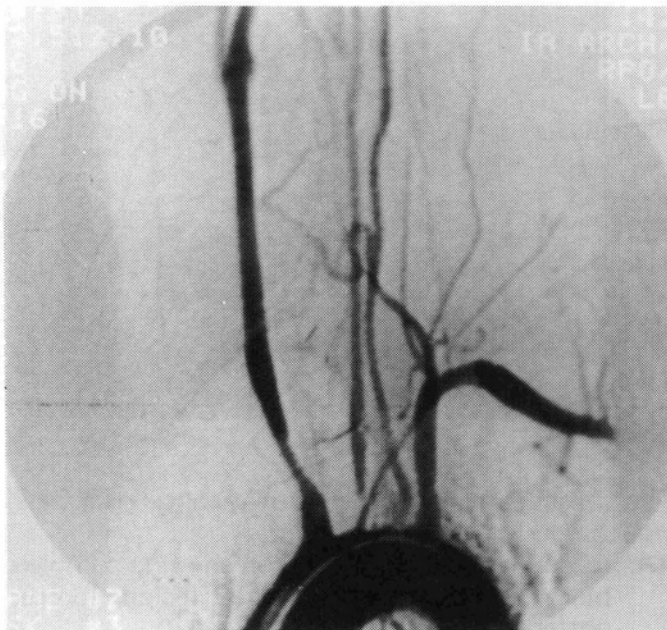


Endovascular Treatment of Stenotic and Thrombotic Lesions of the Supraaortic Arteries

Jacques Théron, m.d.

Angioplasty and recanalization of pathological supraaortic vessels can be successfully performed. This is a case of Takayasu's disease presenting (A) with a narrow stenosis of the right common carotid, left common carotid and left vertebral arteries. The origin of

the right subclavian artery was occluded and a left to right subclavian steal was observed on the late phase. Angioplasty of the stenotic vessels was performed (B) and a complete recanalization of the right subclavian artery is observed.



Spontaneous Spinal Epidural Hematoma

Ruben Kuzniecky, M.D.

Acute spontaneous spinal epidural hematoma is a rare entity. Some 40 cases have previously been reported in the literature.

The epidural hematoma can be localized to any region of the spine and sometimes may extend from the cervical to the lumbar region. Typically, they are in the thoracic or cervico-thoracic region. In most cases, the clinical picture is similar, consisting of acute spinal and radicular pain, followed by motor weakness and sensory complaints, within a short time from the onset of the symptoms.

The term "spontaneous" identifies those patients without any etiological factor in history or pathology. We report a case of a spontaneous spinal hematoma diagnosed by Metrizamide myelography and computed tomography.

A 50 year old man was admitted to hospital with a right hemiplegia. The patient was well few hours before admission when, after bending forward, he experienced an acute onset of severe neck pain with radiation into the right arm; within minutes his right arm and leg became weak. Few minutes later he regain normal usage of his limbs but over the next few hours became severely hemiplegic. His past medical history was unremarkable except for a right inguinal hernia.

Neurological examination revealed normal mental status and cranial nerves. The patient had a right hemiplegia sparing the face, DTR's decreased on the right upper extremity and decreased Pp and light touch on the left side up to C₈.

Metrizamide myelogram revealed a complete block at the level of C₄ (Fig. 1) to T₁ (Fig. 2) and a CT scan (Fig. 3) showed the presence of a right posterior epidural mass displacing the cord anteriorly. A right laminectomy from C₃ to T₁, revealed an epidural clot. There was no evidence of abnormal vessels or other pathology on exam.

One week after the operation the patient has regained use of his lower extremity and continues to improve.

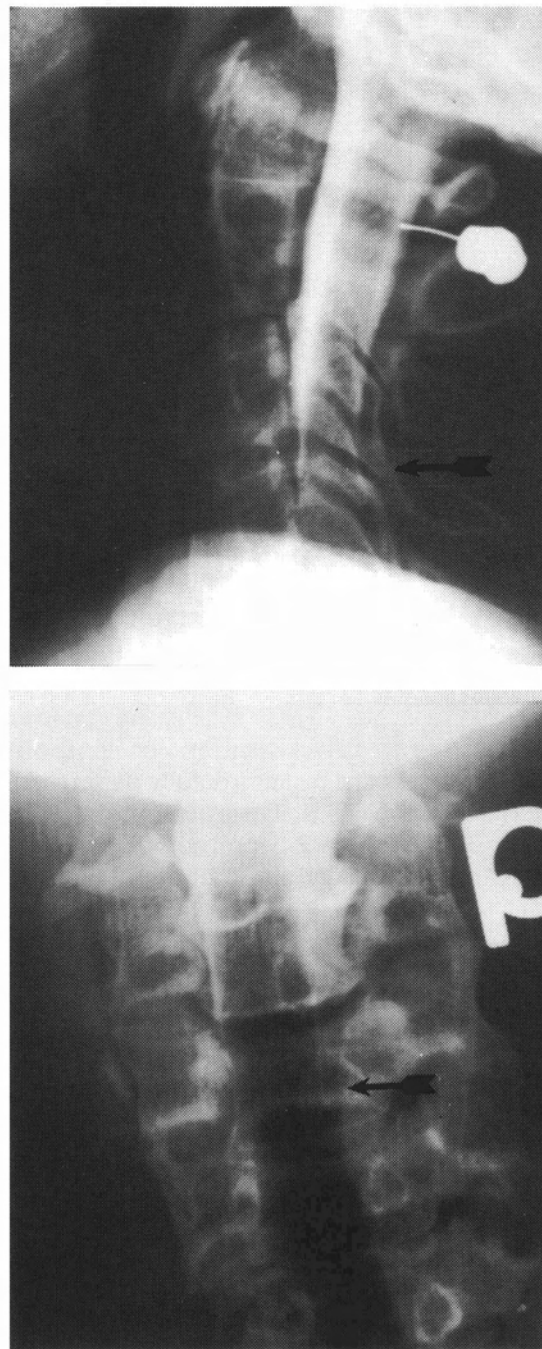


Figure 1
Metrizamide myelography via a lateral cervical C₁-C₂ puncture.

1A: Lateral view of cervical region showing complete block at C₄ from epidural lesion located posteriorly (←).

1B: Frontal view of cervical region showing complete block at C₄ from the right side (←).

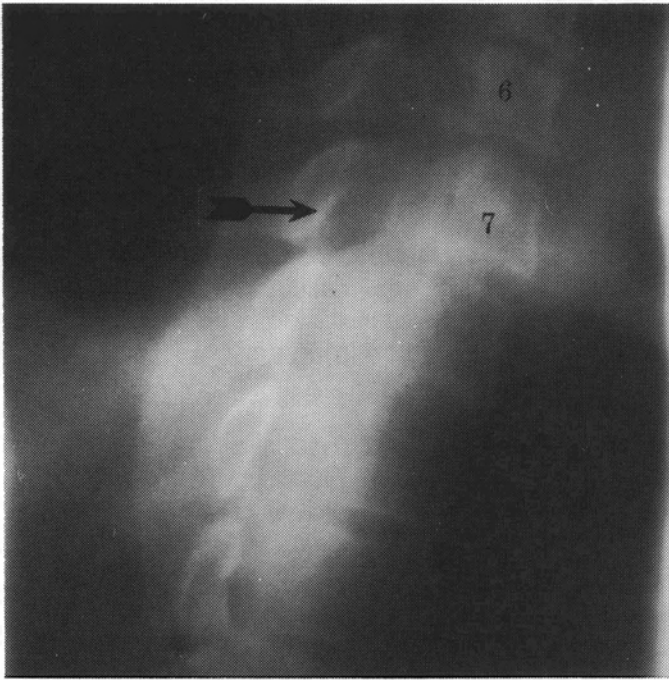


Figure 2
Metrizamide tomo-myelography via a lumbar approach. Complete block at C₆ from right posteriorly (←). Epidural lesion is seen to extend down to upper aspect of T₂.

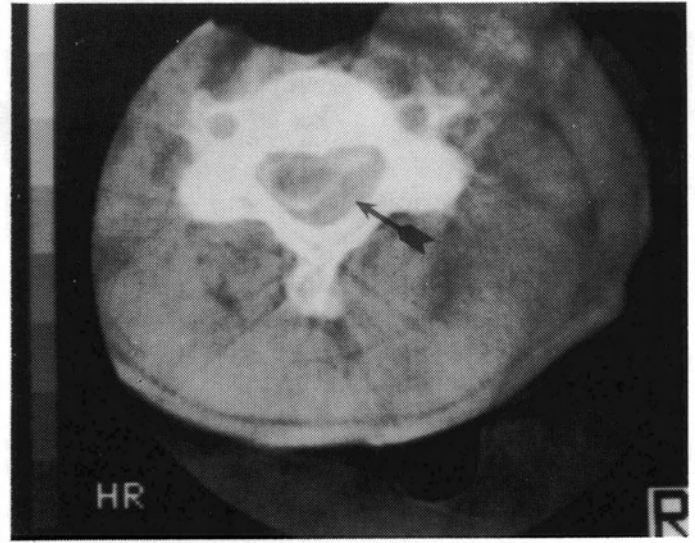


Figure 3
Computed tomography (EMI 5005) following myelography shows the displacement of the cord by the epidural lesion on the right side at C₃ (←).

REFERENCES

- (1) BESTLY R. et al., "Spontaneous cervical epidural hematoma." *J. Neurosurgery*, 61: 143-148, 1984.
- (2) MARKHAM J. et al., "The syndrome of spontaneous spinal epidural hematoma." *J. Neurosurgery*, 26: 334-344, 1967.

Bruxelles-Paris

Denis Melançon, m.d.

J'ai eu le plaisir et l'avantage de visiter deux centres hospitaliers lors d'un récent séjour d'études en Europe, centres disposant tous les deux d'un appareil à Résonance Magnétique. À Bruxelles, où un Gyroscan 0.5 T fonctionne depuis à peu près un an, j'ai apprécié l'hospitalité de Madame Danielle Balériaux et de ses collaborateurs. À Paris, où un GE 1.5 T fonctionne depuis plusieurs mois, j'ai retrouvé le dynamisme du Dr Dominique Doyon. À tous les deux, merci de m'avoir fait part de leur expérience et d'avoir orienté mes connaissances toutes neuves en la matière. Je leur dédie ces images de syringomyélie, conscient qu'ils en ont tous deux produites beaucoup plus déjà.



Fonds de recherche McRae Institut Neurologique de Montréal

Les collègues et amis qui ont connu Donald L. McRae peuvent, en faisant un don, témoigner de leur reconnaissance pour son influence et son enseignement dans le domaine de la Neuroradiologie.

Les sommes recueillies serviront à la promotion de l'enseignement en Neuroradiologie, au développement de nouvelles techniques et à l'organisation des conférences McRae consacrées à l'imagerie Neurologique.

Envoyez votre don à l'adresse suivante:

Montreal Neurological Institute
3801 University, Montréal, Québec, Canada H3A 2B4

McRae Research Fund Montreal Neurological Institute

Friends and colleagues of Donald L. McRae may wish to show their gratitude for his influence and teaching in the field of Neuroradiology.

The proceeds of this fund will be used to promote education in this field, specifically, to develop new techniques in Interventional Radiology and to support the McRae Lecture in Neuro-Imaging.

Send your donation to the following address:

Montreal Neurological Institute
3801 University, Montréal, Québec, Canada H3A 2B4

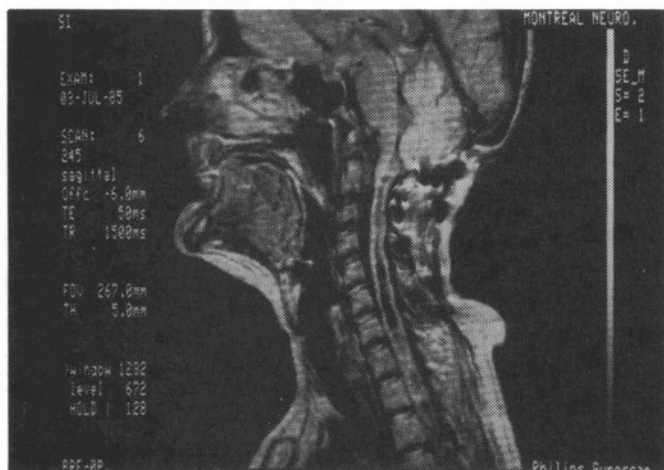


Figure 1
Sagittal section in the spin echo modality (TE 50, TR 1500) disclosing the long cavitation and its segmentations.

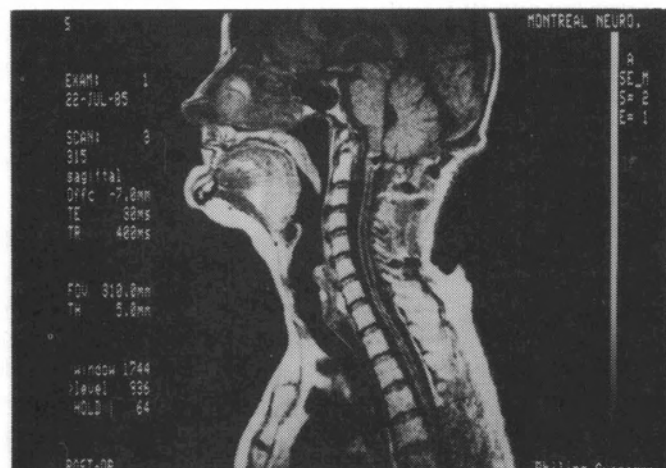


Figure 2
Sagittal section in the spin echo modality but with a shorter time (TE 30, TR 400) showing the reduction in size of the cavity.

Magnetic Resonance Imaging: A preliminary Retrospective

Denis Melançon, m.d.

We have had the advantage of using this new imaging modality for nearly four months and have performed approximately 300 examinations. Its advantages are obvious and mainly twofold:

1. To display the brain morphology almost perfectly;
2. To display disturbed brain tissue via the different T_1 and T_2 relaxation times of matter.

Of particular interest is the clear superiority of MRI to give images of the following:

1. Spinal cord
2. Brain stem and cerebellum
3. Periventricular white matter

The images shown (Figures 1 and 2) are those of a syringomyelic cord before and after myelo-arachnoid shunt. Never before have we been able to see this abnormality and follow its course, so well.

In our next issue, we will show MRI superiority in the posterior fossa lesions and in white matter diseases.

NEUROIMAGE

Volume 2 — Numéro 3 — Proceedings of the MONTREAL NEUROLOGICAL HOSPITAL and INSTITUTE IMAGING DEPARTMENT. Dépôt légal: Bibliothèque nationale du Québec. Rédacteur en chef: Denis Melanson, m.d.. Ont collaboré à ce numéro: R. Kuzniecky, D. Melanson, J. Théron. Conception, réalisation: Jacques L'Estage. Production: Ienmieux (514) 845-0281.