

NEUROIMAGE



VOLUME 19, NUMERO 2
DÉCEMBRE 2003

NEURORADIOLOGY
MUHC-MNH

VOLUME 19, NUMBER 2
DECEMBER 2003

IN THIS ISSUE...

“The Neuro StudyClub Newsletter”

“The International Congress of Radiology”

June 25–29, 2004

Palais de Congrès, Montreal

The Angel Gabriel,
Musée du Québec,
Quebec City

A REMINDER

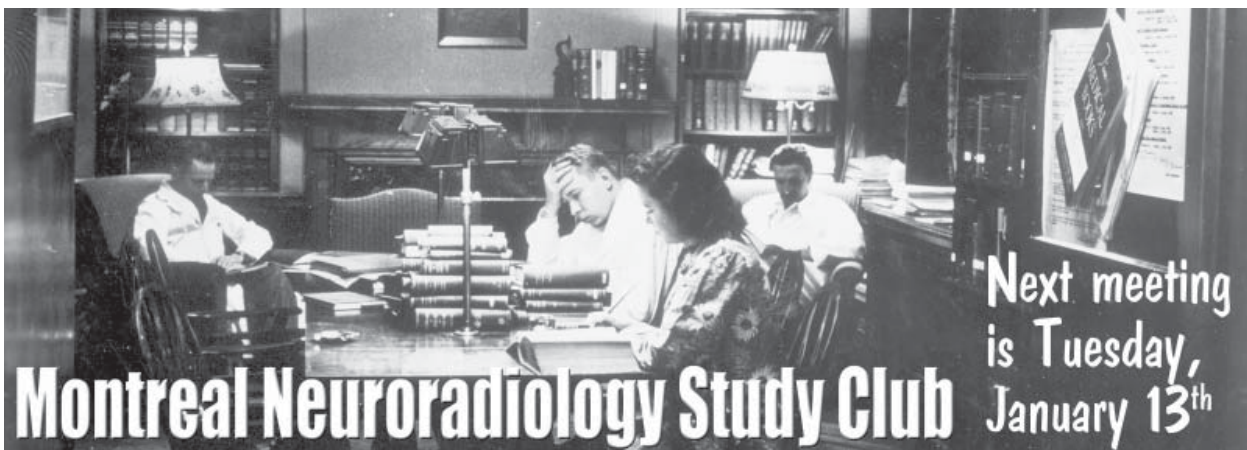
DR. DENIS MELANÇON

Our Neuroradiology Study Club will celebrate its 30th anniversary in 2004. On this occasion, we are planning a special session within the ICR program. I am pleased to extend a special invitation to all our friends who, while in training with us, or while visiting us, have had the opportunity to attend some of our sessions. This gathering will permit us to share memories as well as some most unusual cases. Be sure this special event is noted in your agenda. I hope for a large turnout in order to enjoy the pleasure of your company one last time prior to retirement.

Denis Melançon

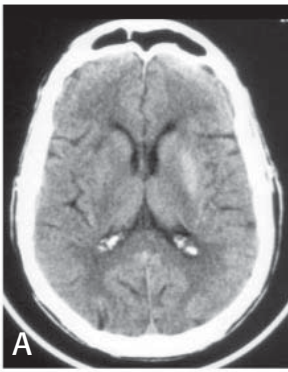


“The International Congress of Radiology”,
June 25–29, 2004, Palais de Congrès, Montreal

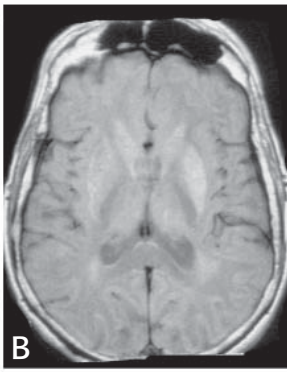


Those who attended the meeting:

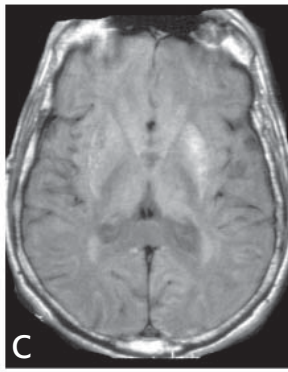
Drs Fontaine, Ribeiro, Chankowski, Ender, Linnel, Nespoli, O’Gorman, Tampieri, Lannes, Vezina, Levental, Saigal, Rendak, Melançon, Nauwelaers



August 21, 2003



August 25, 2003



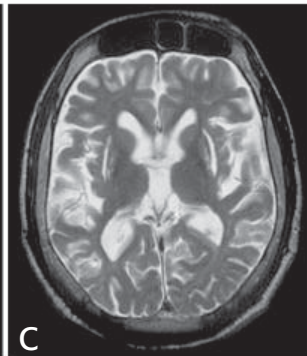
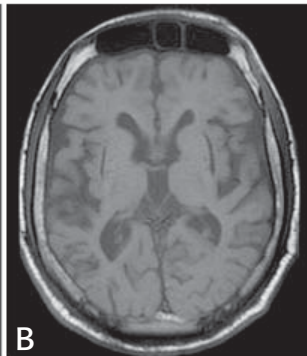
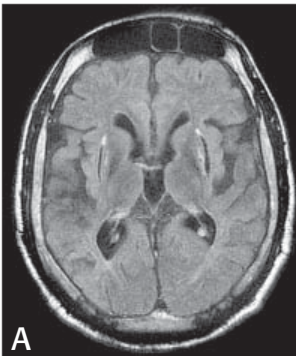
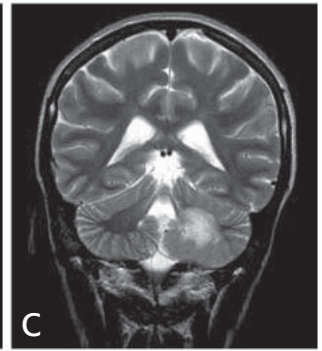
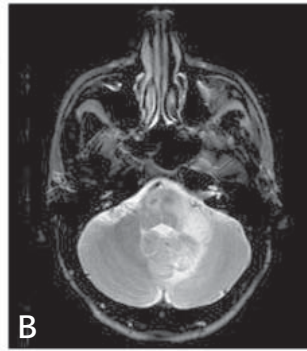
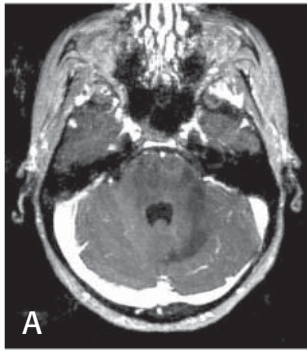
October 30, 2003

This is a patient 70 years old, male, with previous history of diabetes mellitus type II, who presented in August 2003 with hemichorea and hyperglycemia. Final diagnosis was hemichorea induced by non-ketotic hyperglycemia. Striatal hyperdensity is seen on CT and T1-hyperintensity is present on MRI.

Dr. Fontaine

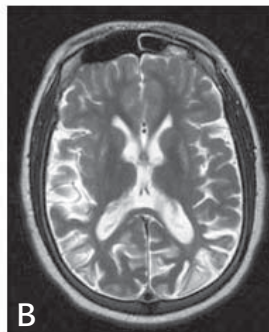
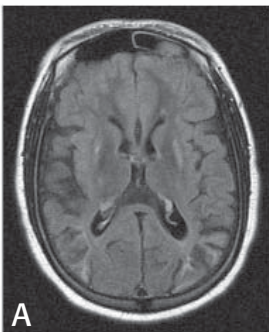
Patient 19 years old, female, with AIDS, and pathologically proven diagnosis of progressive multifocal leucoencephalopathy (PML).

Dr. Tampieri



Wilson's disease showing bilateral putaminal necrosis and diffuse brain atrophy

Dr. O'Gorman



Wilson's disease showing bilateral putaminal hyperintensity on T1 and T2, and multiple cortical ischemic lesions.

Dr. O'Gorman

You can bring your cases on films or CD's – R.S.V.P. by calling 398-1908 or faxing 398-2829.

Also please note that the meeting now starts at 6PM (18hrs) and don't forget to sign the attendance sheet.

Best regards
Respetos Saluti affettuosi Filika
Amicalement Afectuosamente
Saudações Namaste Herzliche Gruesse
O Genki De As-salaam alaykum Cordialmente

Wishing you a successful

2004

Les Plaines d'Abraham, Quebec City

THIS NEWSLETTER IS SPONSORED BY

Department of Radiology MUHC/MNH &
Volume 19 – number 2 – Bibliothèque nationale, ISSN 1180-0844 National Library of
Canada, Production – Denis Melanson, Luciana Torres-Ribeiro, Paola Nespoli – Neurikon
Inc. Layout, Graphic Design, and some Photography by the Department of NeuroPhoto-
graphy at the Montreal Neurological Hospital (12-2003)

