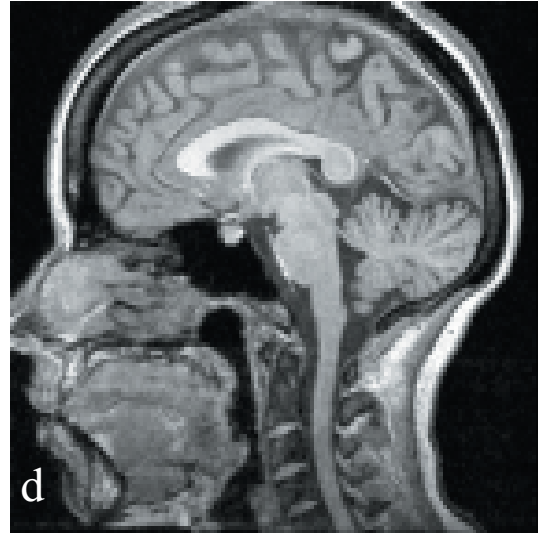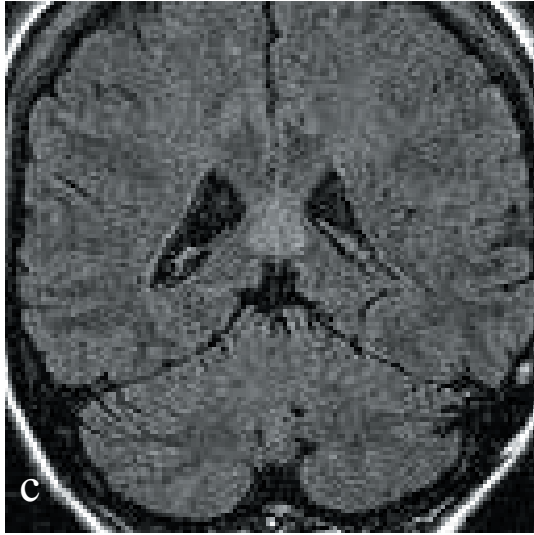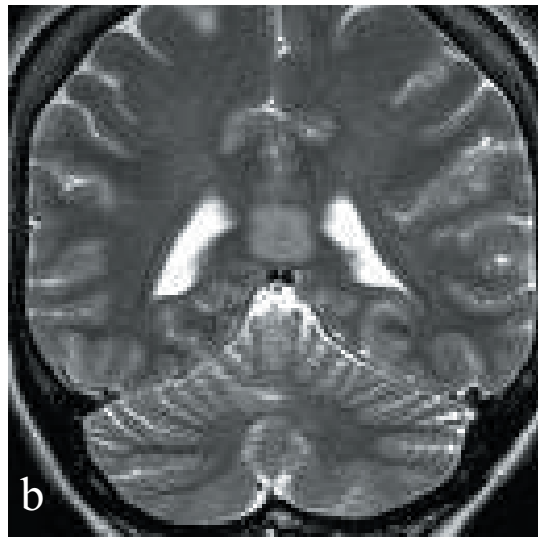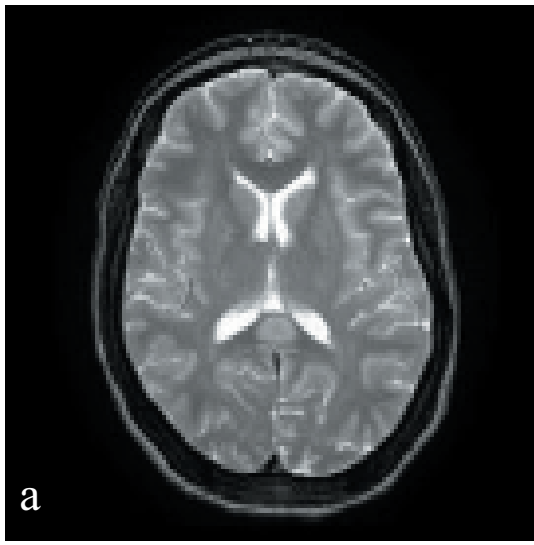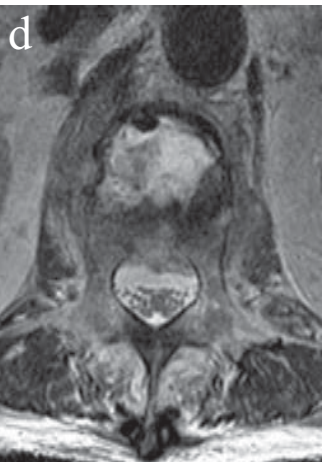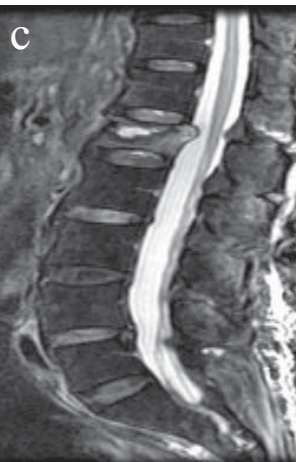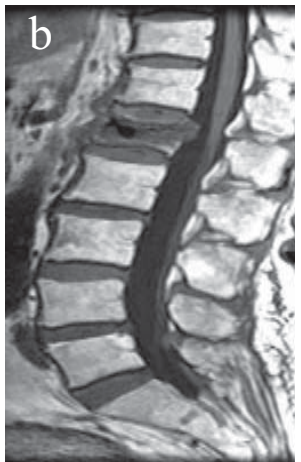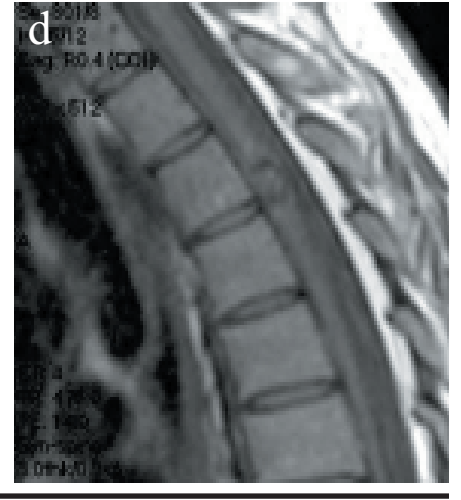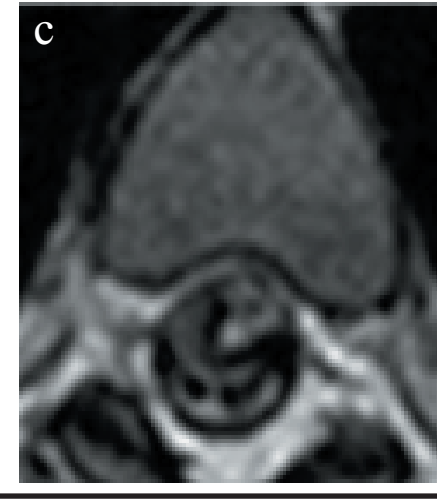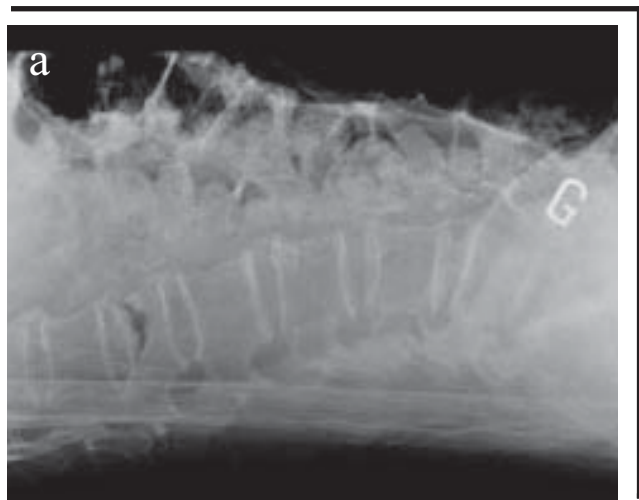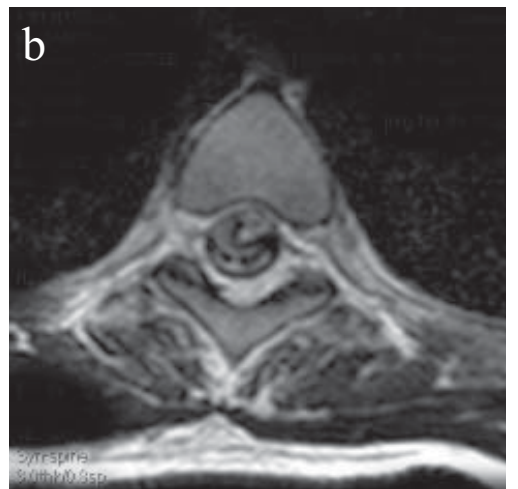


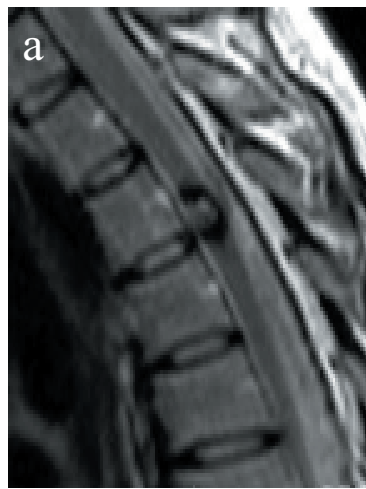↖
Dr Carrara:
*focal callosal lesion,
 reversible, related to
 anti-epileptic medica-
 tions*

Dr. Fontaine:
 cavernoma of spinal cord
 ➤



↖
Dr. Fontaine:
 Kummel's disease

Cases discussed at the June Study Club

...

Dr Tampieri

hemangiopericytoma, naso-ethmoid

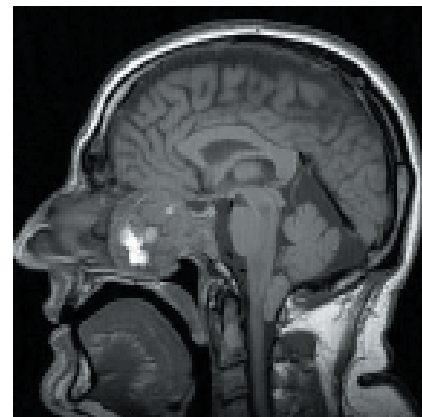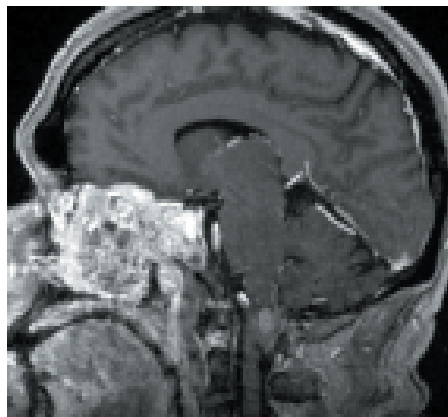
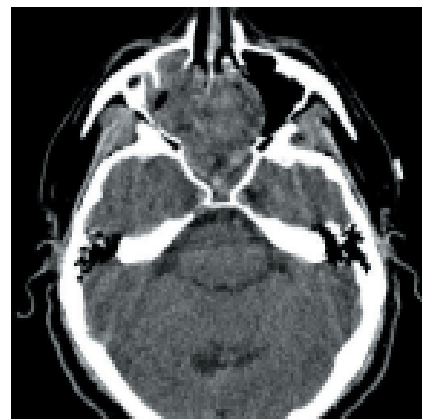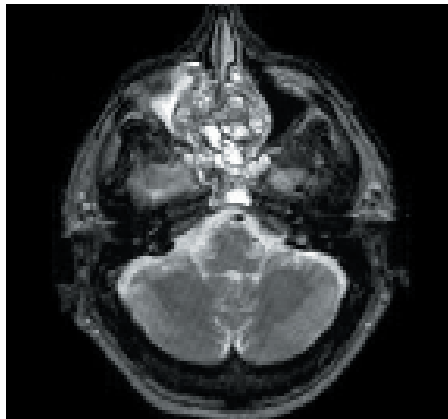
Dr Carrara

focal callosal lesion, reversible, related to anti-epileptic medications

Dr Fontaine

cavernoma of spinal cord

Dr Fontaine

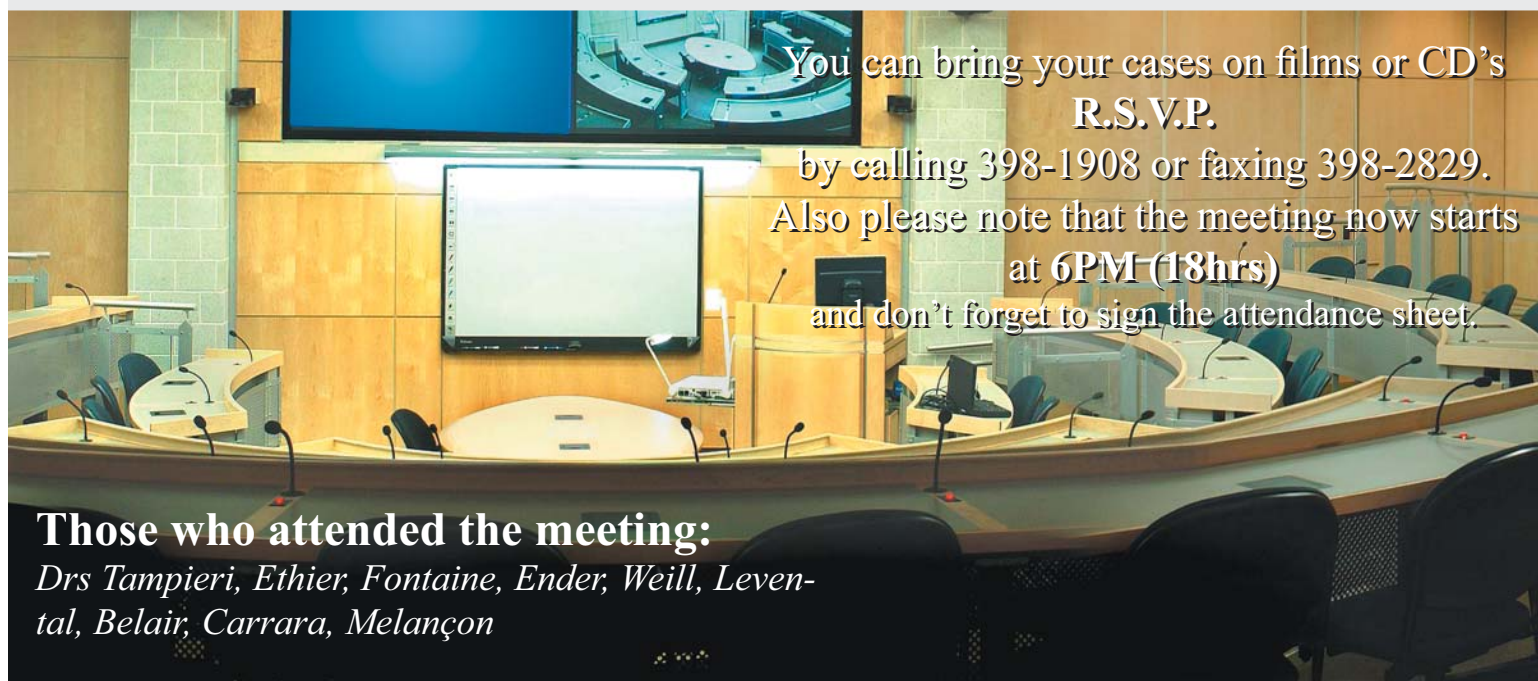


Dr. Tampieri: *hemangiopericytoma, naso-ethmoid*



The next meeting on September 14th will be held in the Jeanne Timmins Amphitheatre. As for the October Meeting, we have planned for it to take place in Ottawa, on October 12th. Mark the date now.

And please note that the proceedings of the 30th anniversary meeting, held at the Intercontinental Hotel in Montreal, will be published in the next Neuro Image.



You can bring your cases on films or CD's
R.S.V.P.

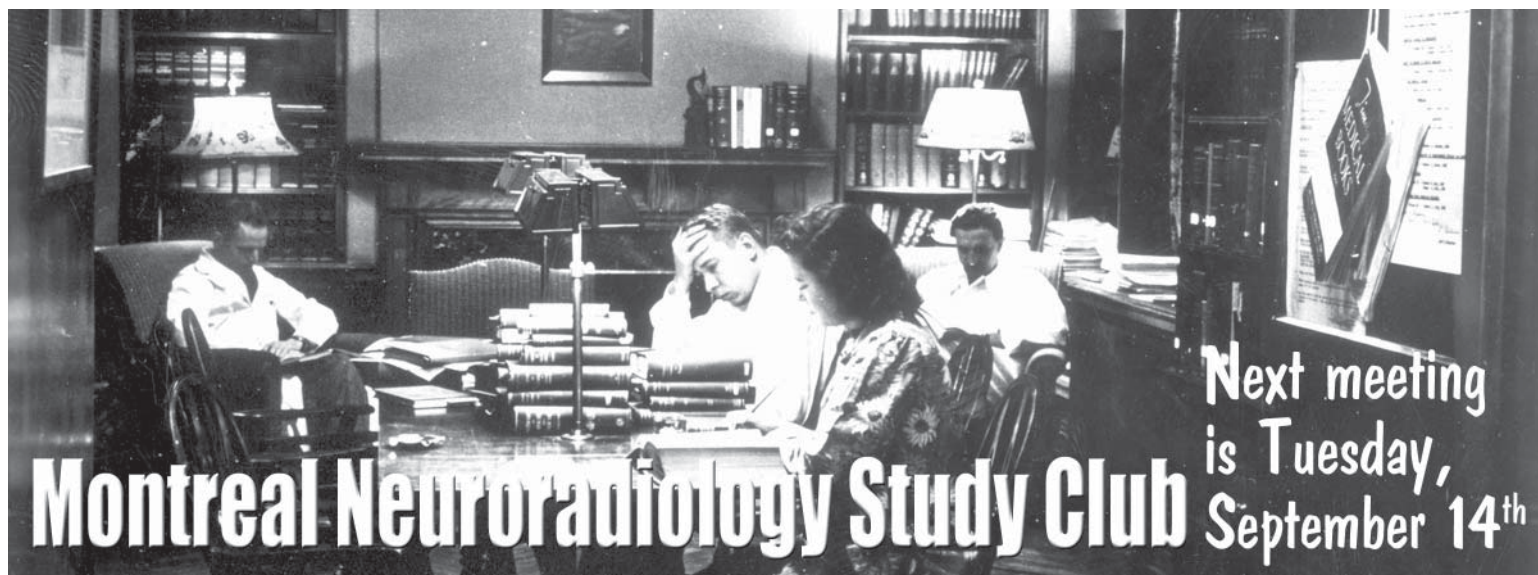
by calling 398-1908 or faxing 398-2829.

Also please note that the meeting now starts
at 6PM (18hrs)

and don't forget to sign the attendance sheet.

Those who attended the meeting:

Drs Tampieri, Ethier, Fontaine, Ender, Weill, Levental, Belair, Carrara, Melançon



Montreal Neuroradiology Study Club

Next meeting
is Tuesday,
September 14th