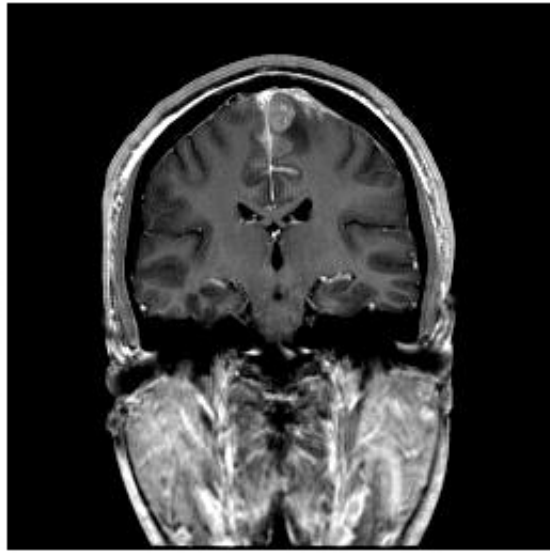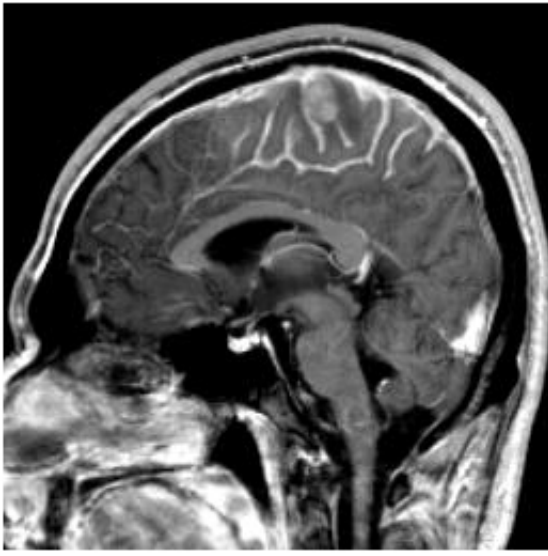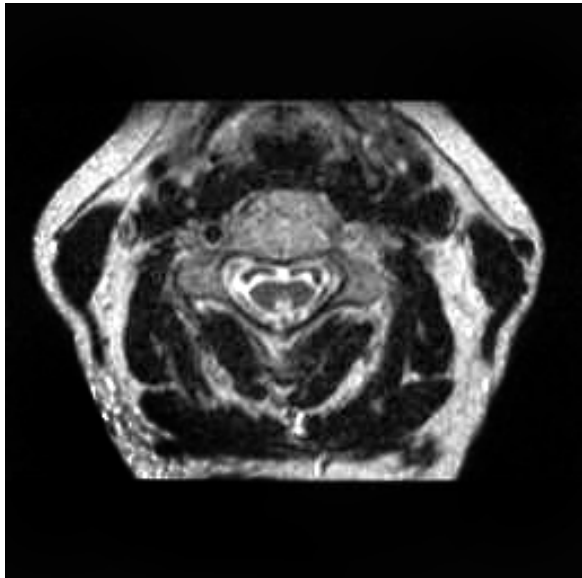
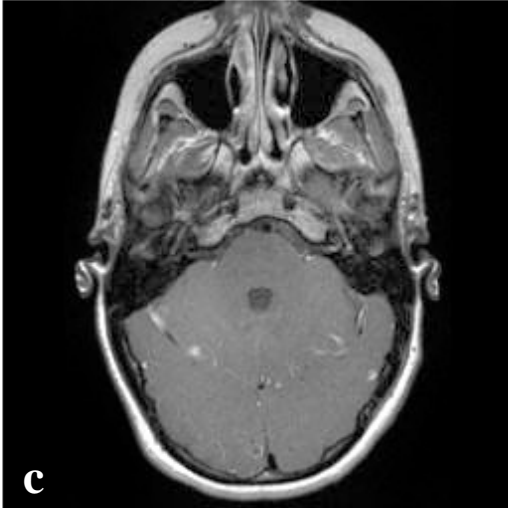
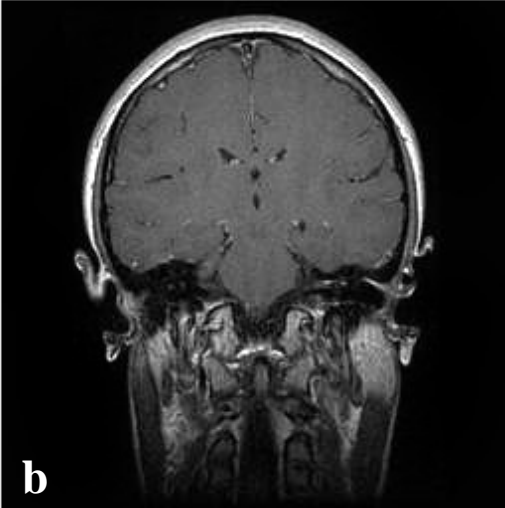
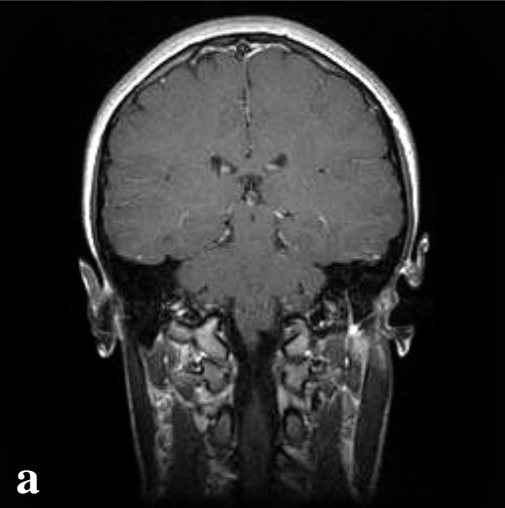
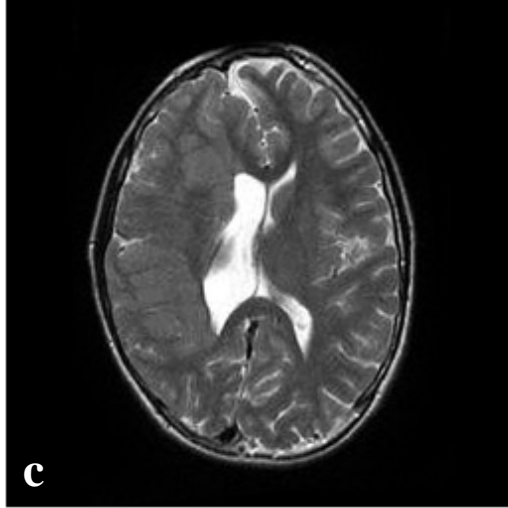
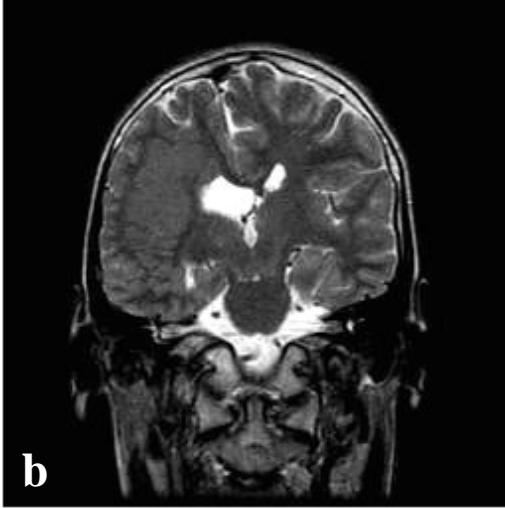


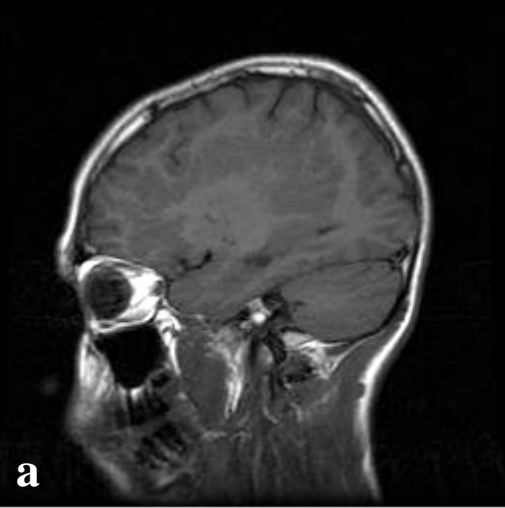Dr. Melançon:
Leptomeningeal melanoma
◀

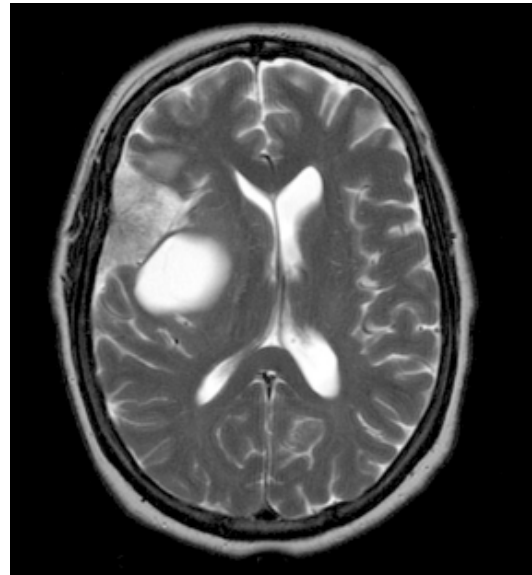
Dr. O’Gorman:
(a,b,c) Periventricular heterotopia associated with abnormal cortex.
▼



◀ **Dr. Chankowsky:**
Left vertebral dissection associated with ischemic myelopathy

▲ **Dr. O’Gorman:**
(a,b,c) Left seventh nerve palsy

Dr. Fontaine:
Cystic meningioma ▶



Cases discussed at the September Study Club ..

DR MELANÇON:

- Primary intracranial leptomeningeal melanoma

DR O'GORMAN:

- Periventricular heterotopia associated with abnormal cortex.
- Left seventh nerve palsy: enhancing portions of facial nerve

DR CHANKOWSKY:

- Left vertebral artery dissection associated with ischemic myelopathy

DR FONTAINE:

- Cystic meningioma

Those who attended the meeting:

Drs Fontaine, Ribeiro, Ender, Linnel, Nespoli, Lafaille, Chankowsky, Melançon, O'Gorman, Saigal

