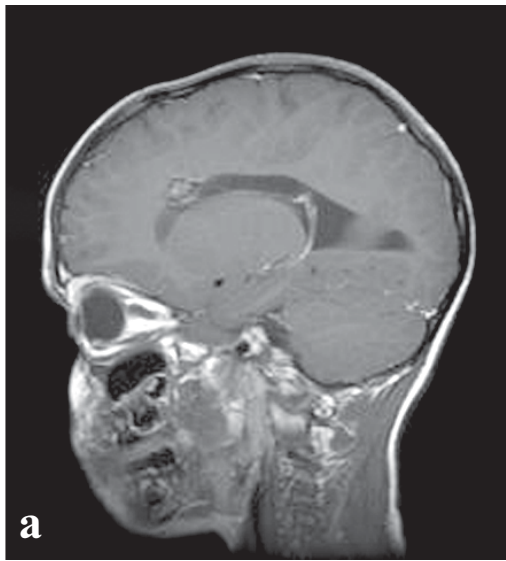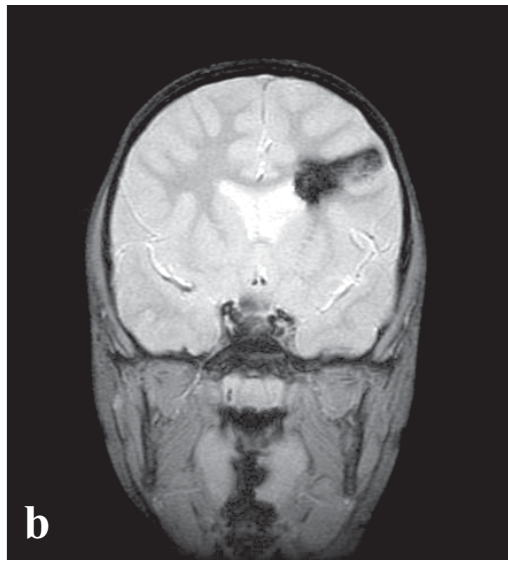
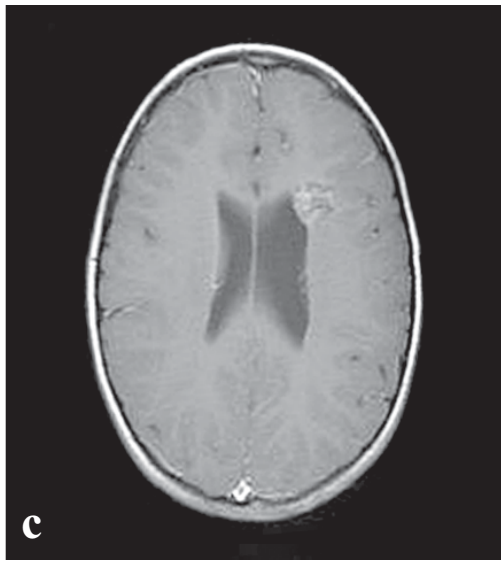




a



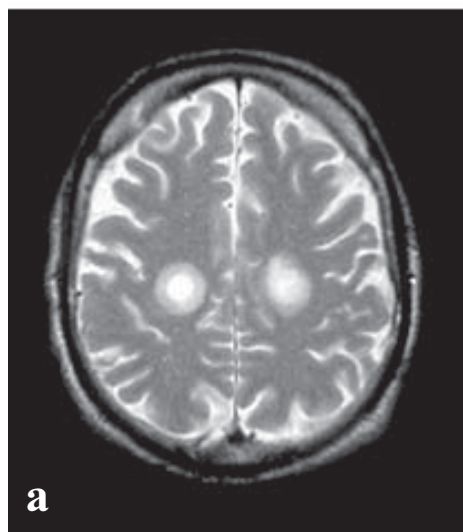
b



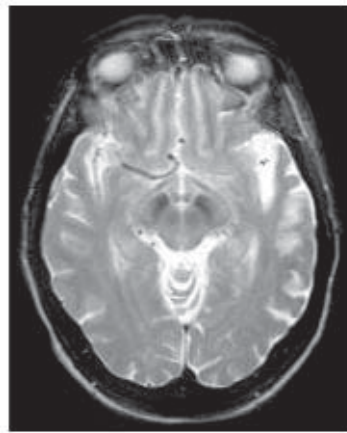
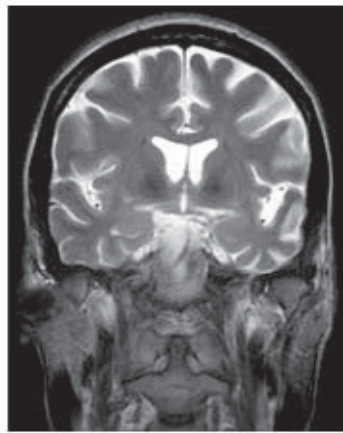
c

▲ Dr. O’Gorman:

(a,b,c) Left frontal cavernous angioma

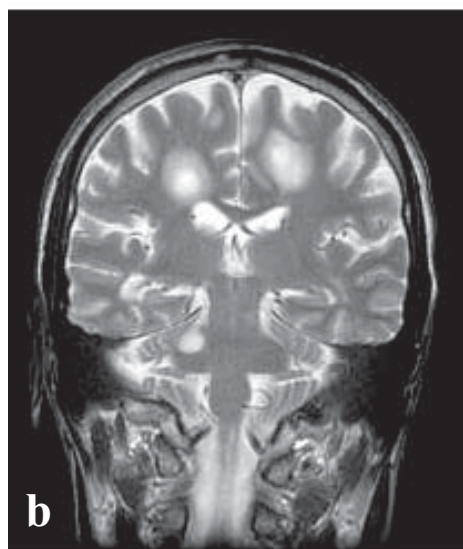


a

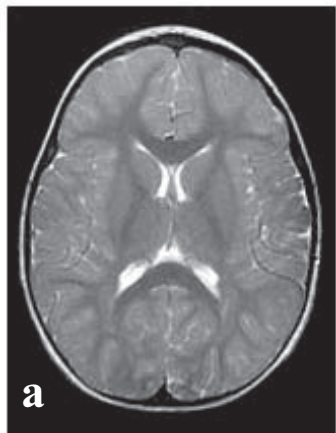


▶ Dr. Tampieri:

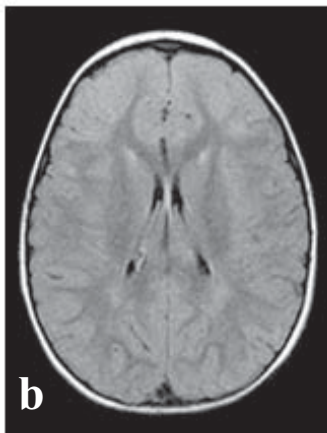
(a,b) Left superior temporal gyrus atrophy, probable primary



b



a

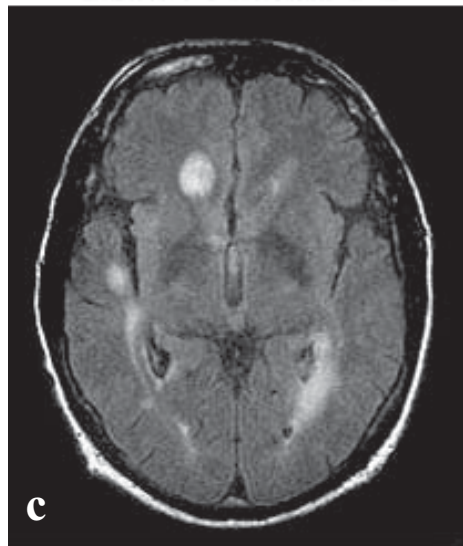


b

◀ Dr.

O’Gorman:

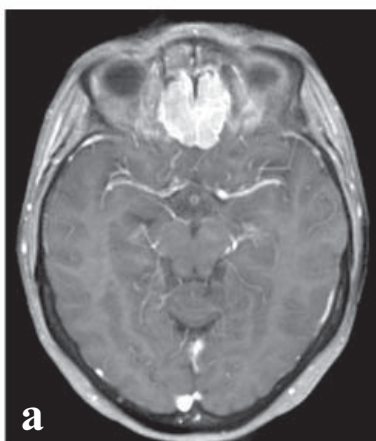
(a,b) Bifrontal cortical



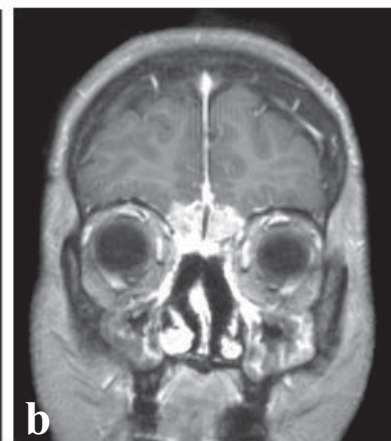c

▶ Dr. Tampieri:

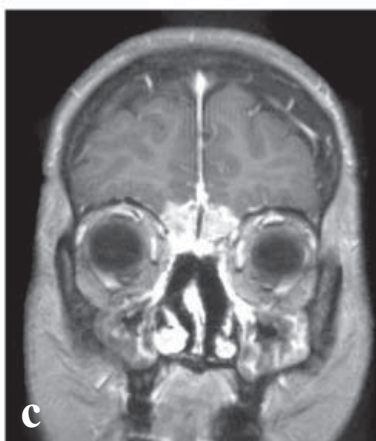(a,b,c,d)
Esthesio-neuroblastoma



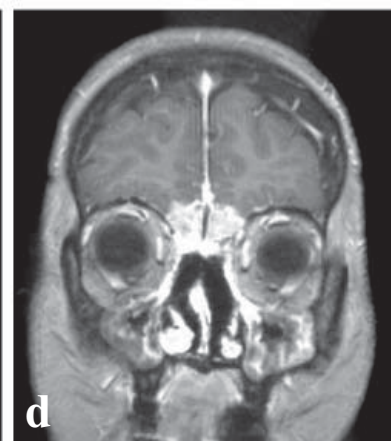a



b



c



d



▲ Dr. Chankowsky:

(a,b,c) Demyelinating disease

Cases discussed at the October Study Club

...

DR O'GORMAN:

- Left frontal cavernous angioma
- Bifrontal cortical hyperintensity

DR TAMPIERI:

- Left superior temporal gyrus atrophy, probable primary progressive aphasia
- Esthesioneuroblastoma

Those who attended the meeting:

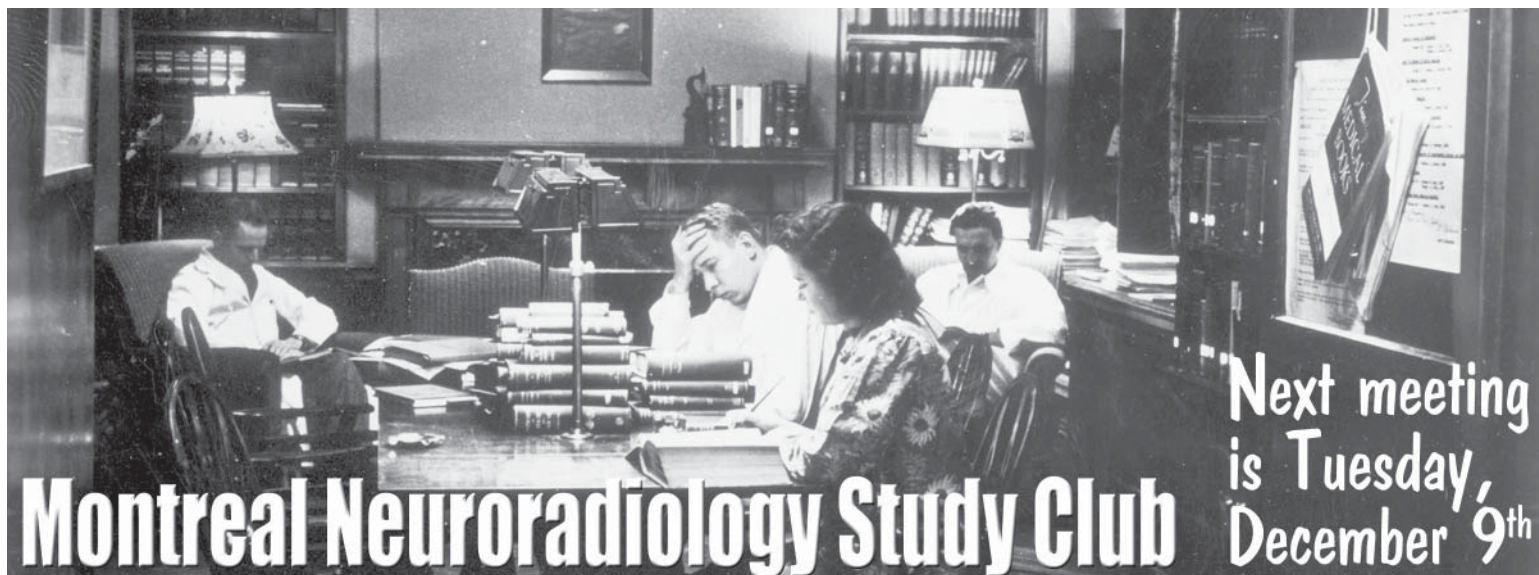
Drs Fontaine, Ribeiro, Ender, Linnel, Nespoli, Chankowsky, O'Gorman, Del Carpio, Bélair, Tampieri, Ethier, Feteih, Gill, Camlioglu, Nauwelaers, Weill



This study club is made possible from a contribution by

BERLEX CANADA INC.

You can bring your cases on films or CD's – R.S.V.P. by calling 398-1908 or faxing 398-2829. Also please note that the meeting now starts at 6PM (18hrs) and don't forget to sign the attendance sheet.



Montreal Neuroradiology Study Club

Next meeting
is Tuesday,
December 9th