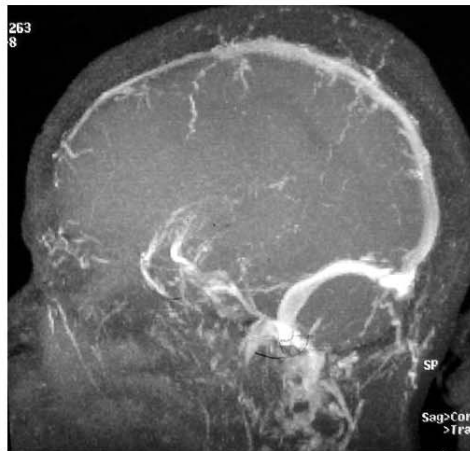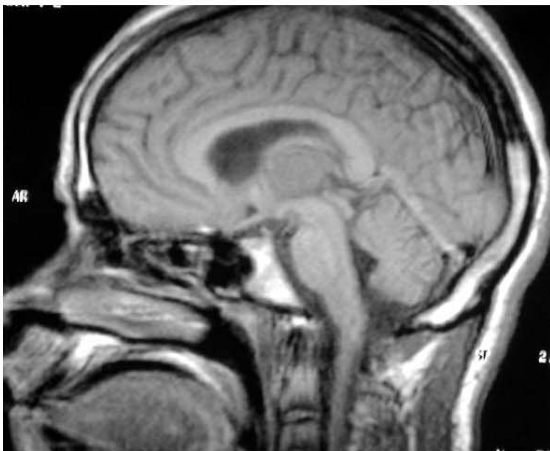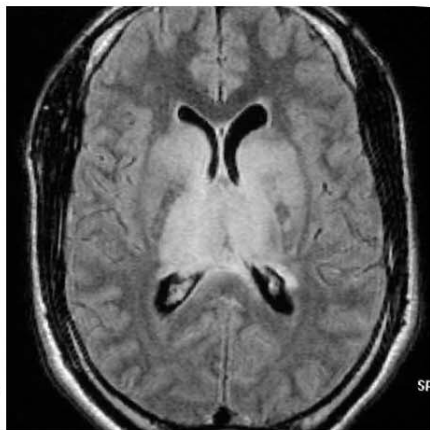
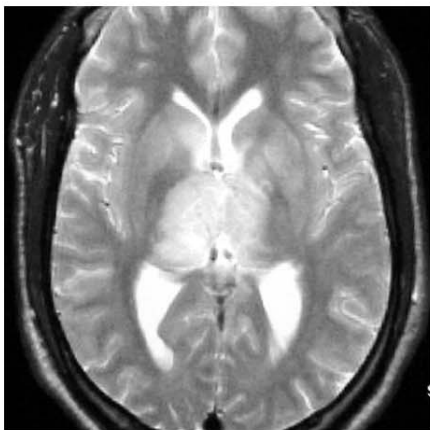
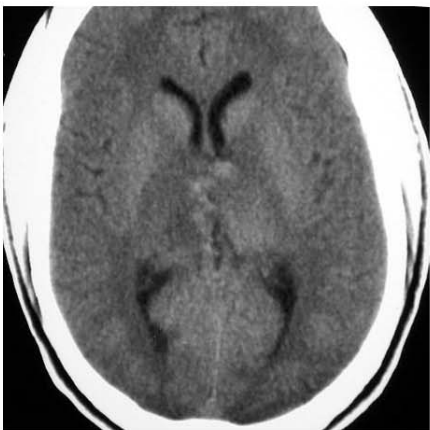


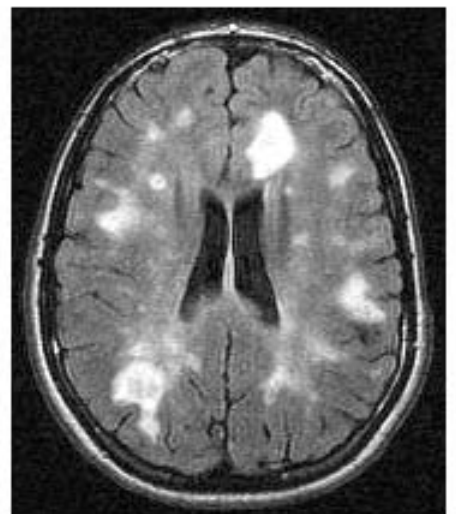
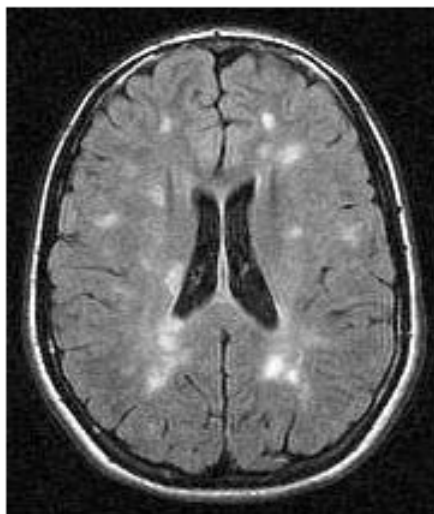
Some Images from April's Study Club:



Dr Gilbert: Deep venous thrombosis (CT, MR, MRV)



2001

2002

Drs del Carpio and Melançon: Demyelinating disease (MS?) in adolescence (age 15-16 years)

Cases discussed at the April Study Club ...

DR GILBERT:

- ⌘ Deep venous thrombosis
- ⌘ Recurring WM lesions, upper brain stem, ADEM?

DR TAMPIERI:

- ⌘ Typical lesions for MS, incidental
- ⌘ Epidural abscess, lumbar
- ⌘ Basilar artery thrombosis
- ⌘ Angiography in brain death

DR FONTAINE:

- ⌘ Fibrous dysplasia of skull, CT and MR
- ⌘ MS versus ADEM

DR LEVENTAL:

- ⌘ Meningeal carcinomatosis
- ⌘ Cranial and spinal subdurals, concomitant, on Coumadin

DRS DEL CARPIO AND CHANKOWSKY:

- ⌘ Multiple septic emboli

DR BELAIR:

- ⌘ Cerebellar abscess
- ⌘ Unusual conus medullaris, variant of diplomyelia?
- ⌘ Cord compression by disc, edema and enhancement
- ⌘ Histiocytosis of hypothalamus

Those who attended the meeting:

Drs Gilbert, Levental, Fontaine, Tampieri, del Carpio, Chankowsky, Bélair, Weill, Lafontaine, Ethier, Vézina, Ferraris, Melançon.

PLEASE NOTE THAT THE MEETING NOW STARTS AT 6PM-18HRS and don't forget to sign the attendance sheet

You can bring your cases on films or CD's
R.S.V.P. by calling 398•1908 or faxing 398•2829

FUTURE MEETINGS:

Another trip to Ottawa is in the planning • Berlex is looking at Redpath Museum as site of eventual CHUM-MUHC meeting

This study club is made possible from a contribution by

BERLEX CANADA INC.

