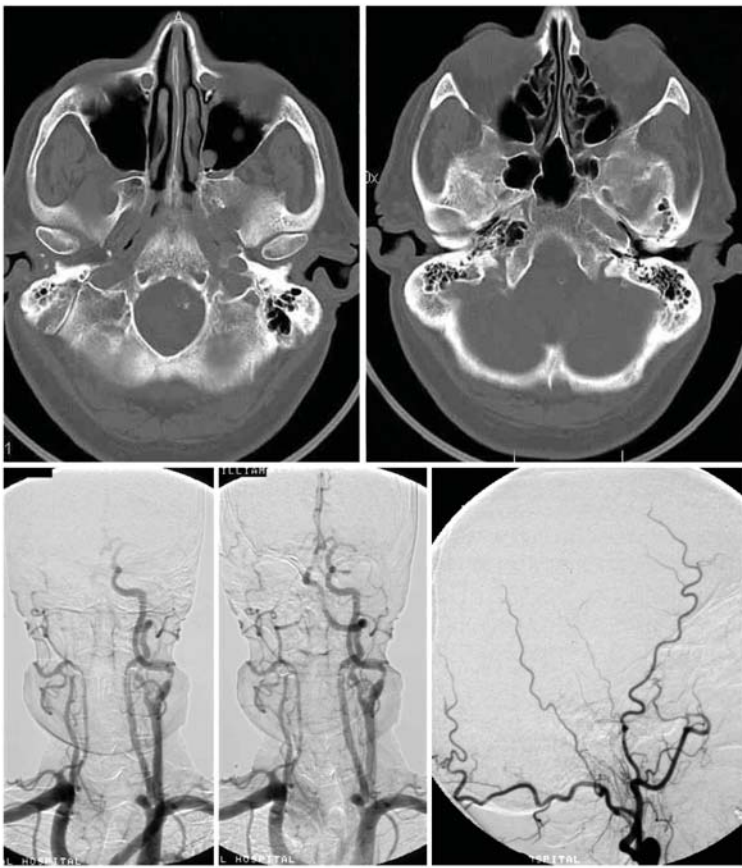
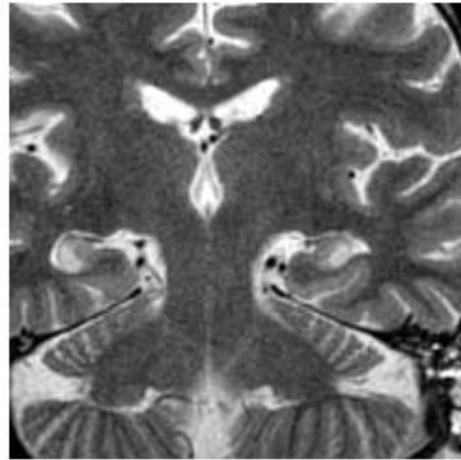
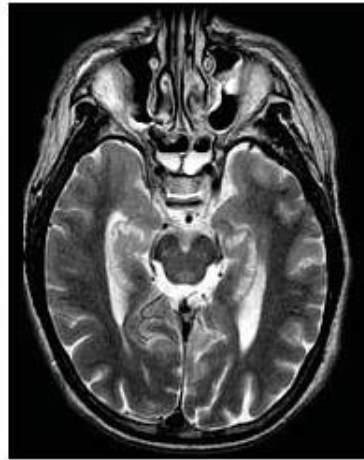
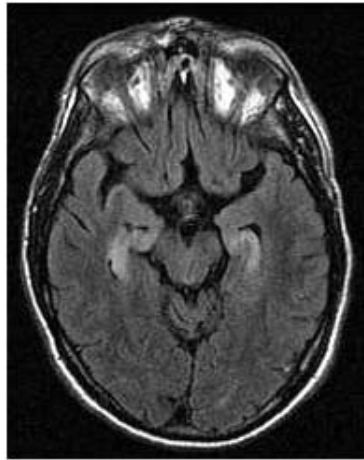
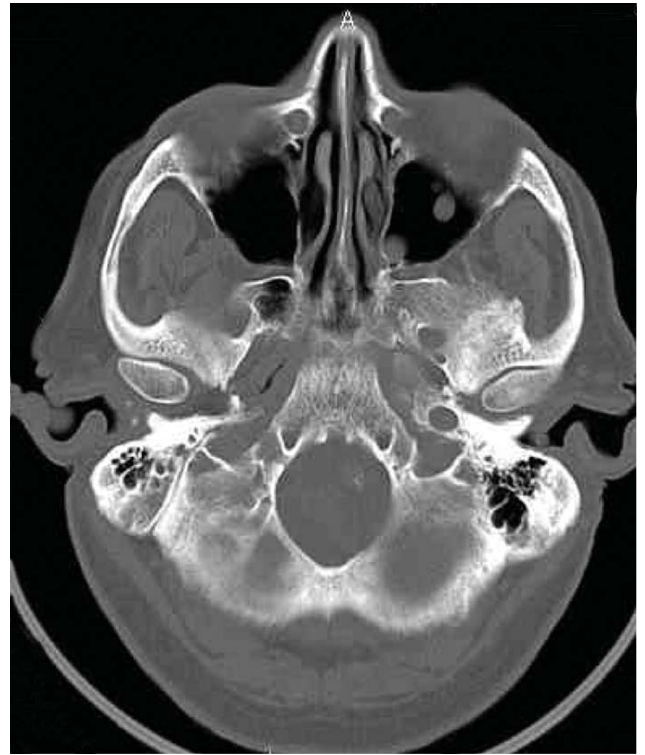

Dr Tampieri: Agenesis of internal carotid artery

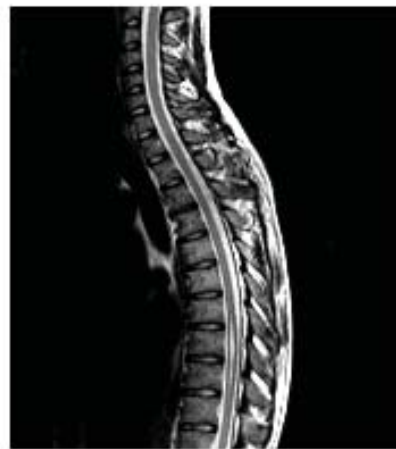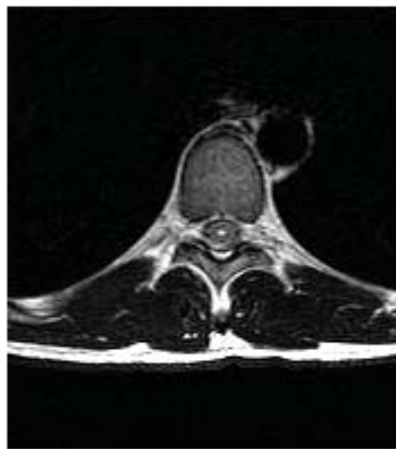


Arch

RCC

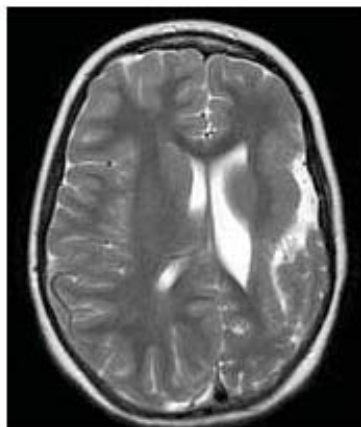
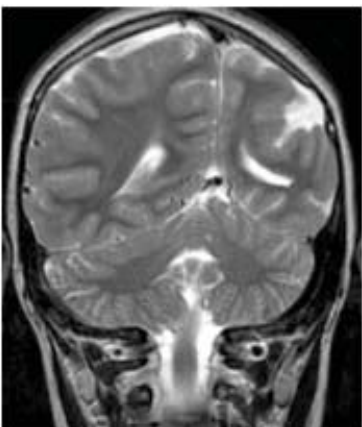


Dr del Carpio: Bilateral hippocampal edema in status epilepticus

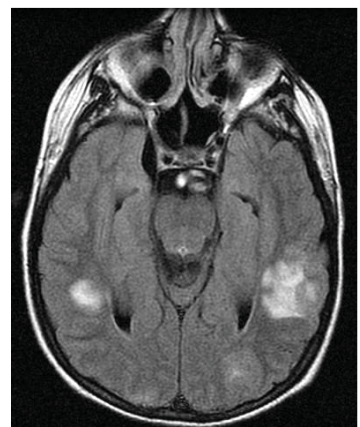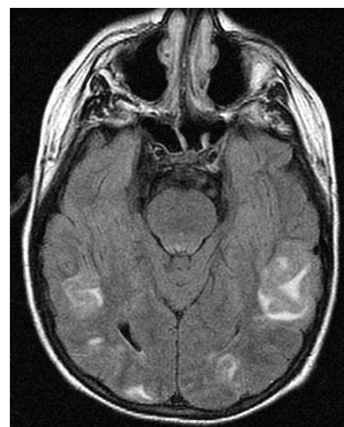


Dr Fontaine:
Persistent central canal

Dr O'Gorman:



Polymicrogyria



Reversible posterior circulation edema

Cases discussed at the February Study Club ...

DR BRASSARD

⌘ *Neuroacanthocytosis*

DR FONTAINE

⌘ *Neurinoma, L1-L2 foramen*

⌘ *Persistent central canal*

⌘ *Lumbar synovial cyst*

DR TAMPIERI

⌘ *Agenesis of internal carotid artery*

DR DEL CARPIO

⌘ *Bilateral hippocampal edema in status epilepticus*

DR O'GORMAN

⌘ *Polymicrogyria*

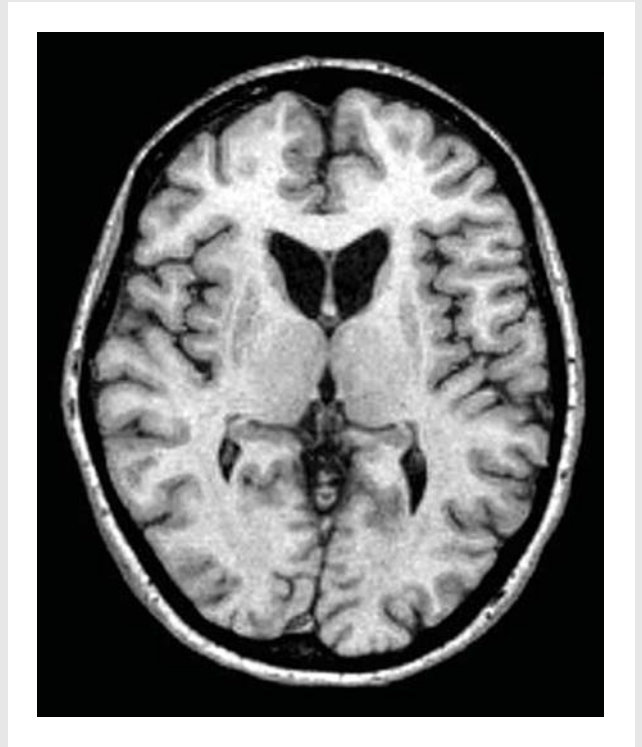⌘ *Reversible posterior circulation edema*

DR MELANÇON

⌘ *Sacral meningocele*

DR LEVENTHAL

⌘ *Hemangioblastoma*



Dr Brassard:

Neuroacanthocytosis –
Atrophy of caudate and putamen, bilateral
Reference: J Neurol (2001) 248: 87-94

PLEASE NOTE THAT THE MEETING NOW STARTS AT 6PM-18HRS

You can bring your cases on films or CD's **R.S.V.P.** by calling 398•1908 or faxing 398•2829

AND DON'T FORGET TO SIGN THE ATTENDANCE SHEET

BERLEX CANADA INC.
generous contribution by Berlex Canada Inc.
This study club is made possible from a

Those who attended the meeting:
Drs Ethier, Tampieri, Brassard, Fontaine, del Carpio, Denegri, Ferraris, Weill, O'Gorman, Ender, Leventhal, Nauwelaërs, Hall, Achram, Stavros, Arbulú, Ayala.

