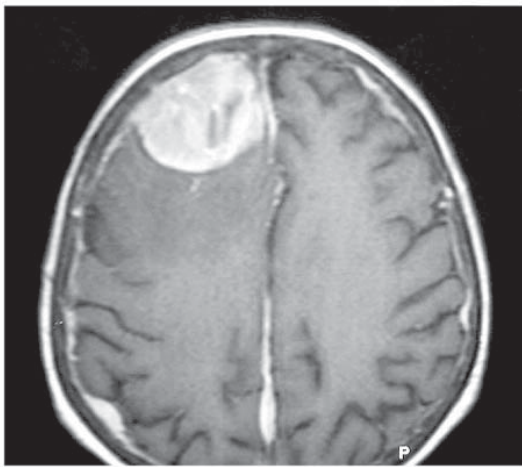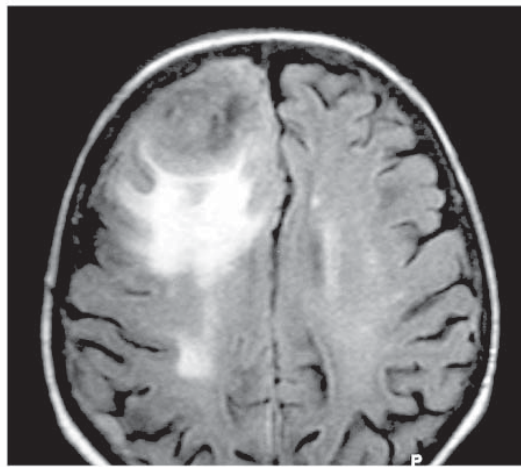
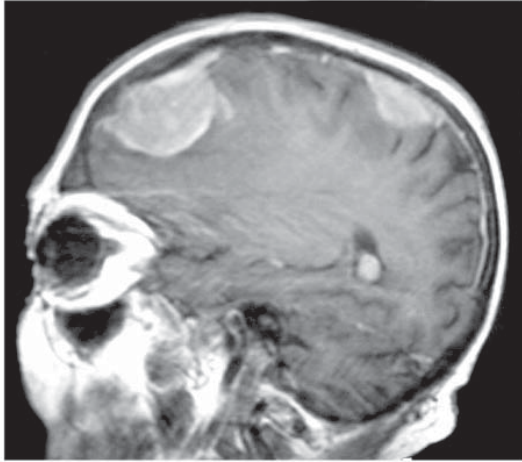


T1 GADO

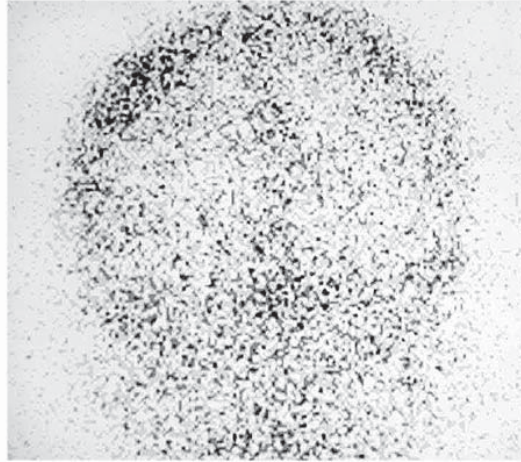


FLAIR

**Dr Levental:**  
Cranial epidural lesions  
of extramedullary he-  
matopoiesis, in a case  
of polycythemia vera.

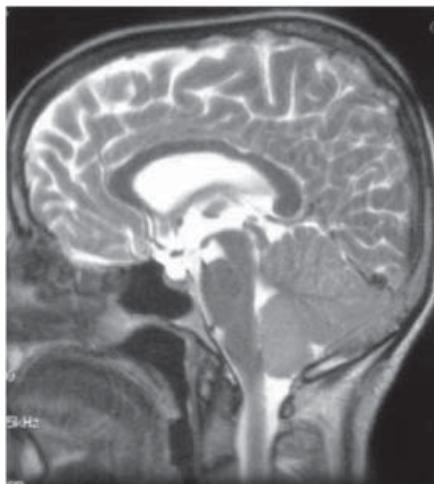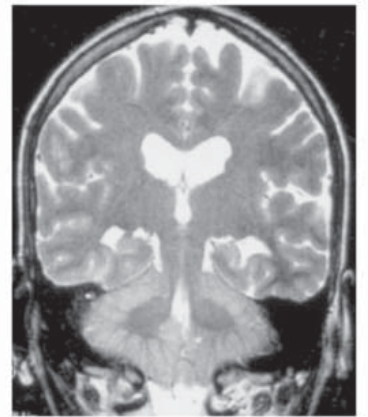
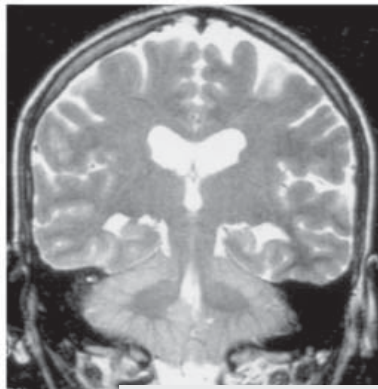
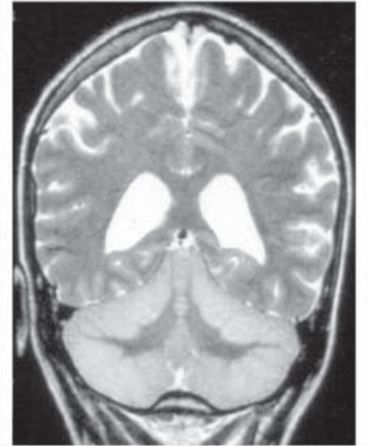
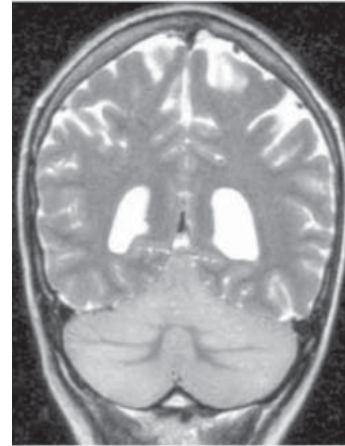
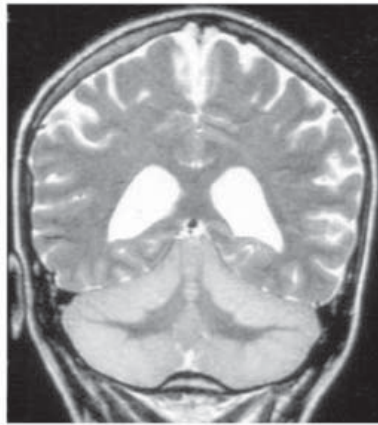
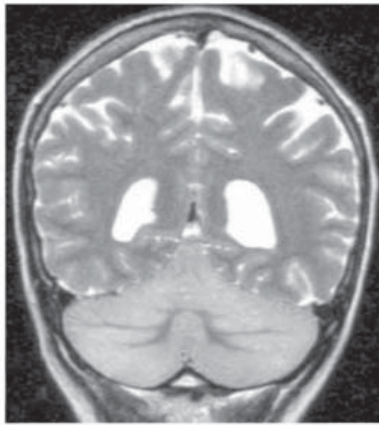


T1- GADO

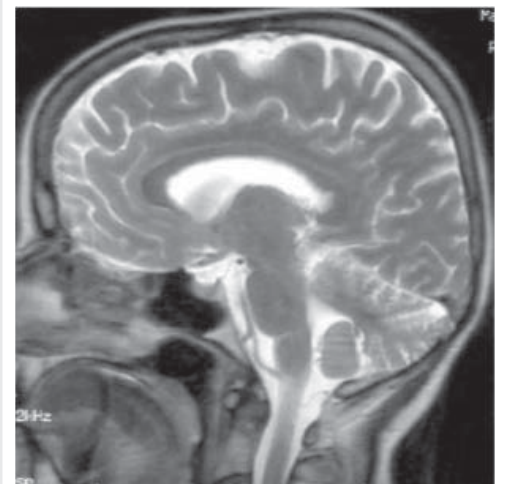

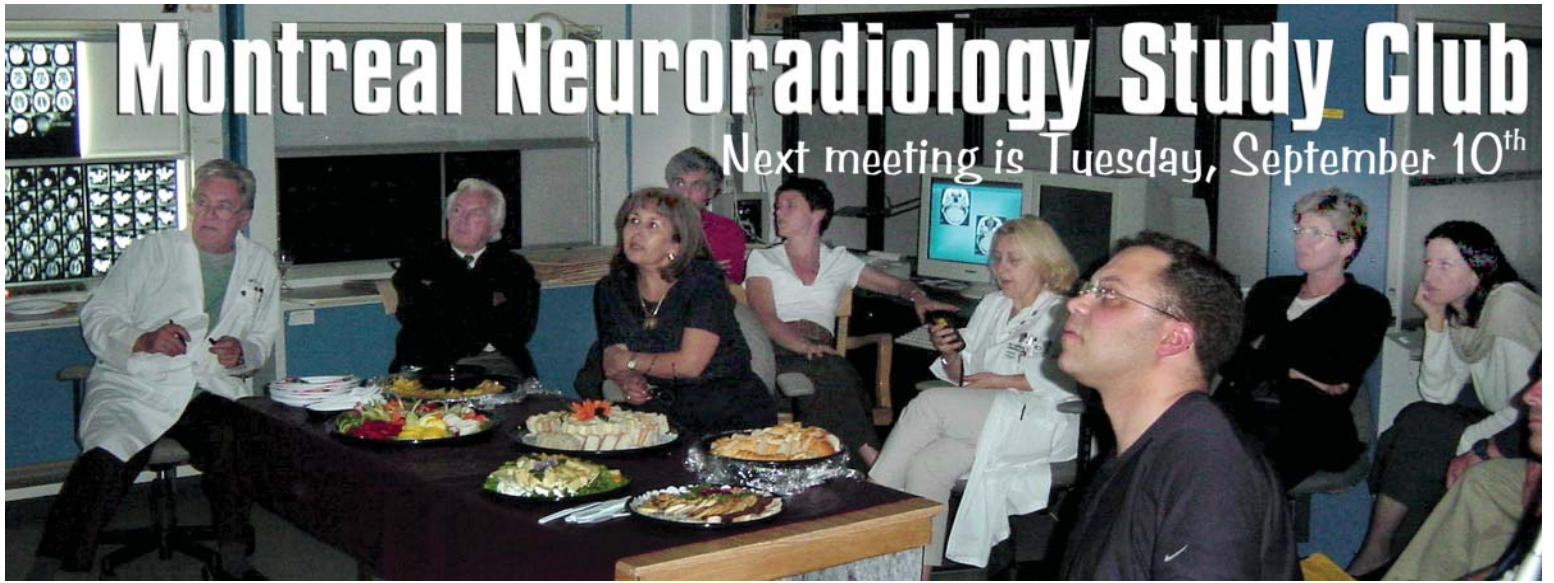Nuclear Scan

**Dr Fontaine:**  
Post-viral polyocerebellitis



with complete resolution ➤





PLEASE  
NOTE THAT THE  
MEETING STARTS AT 6PM-18HRS and  
don't forget to sign the attendance sheet

You  
can bring your cases on  
films or CD's  
**R.S.V.P.** by  
calling 398•1908 or faxing 398•2829

FUTURE  
MEETINGS:  
Berlex is looking at BTRC as site of eventual  
CHUM-MUHC meeting

This study club is made possible from a contribution by  
**BERLEX CANADA INC.**

## Cases discussed at the June Study Club ...

### DR TAMPIERI:

- Exophytic thoracic cord tumour: hemangioma

### DR DEL CARPIO:

- Bilateral hippocampal lesions, status epilepticus or acute psychosis?

### DR CHANKOWSKY:

- Petro-mastoid 7<sup>th</sup> nerve involvement in parotid gland inflammation
- Fistula, middle ear/semi-circular canal.

### DR FONTAINE:

- Post-viral polyocerebellitis, with complete resolution
- 82 year old lady with tethered cord

### DR O'GORMAN:

- A case of hemiplegic migraine

### DR MELANÇON:

- Von Hippel-Landau: a renal cell carcinoma metastasis into a thoracic cord hemangio-

blastoma



### Those who attended the meeting:

*Drs Tampieri, Ender, Chankowsky, Lafontaine, Ferraris, Rosati, Vezina, Fontaine, del Carpio, O'Gorman, Melançon, Mrs D'Onofrio and Campeau, from Berlex Canada*