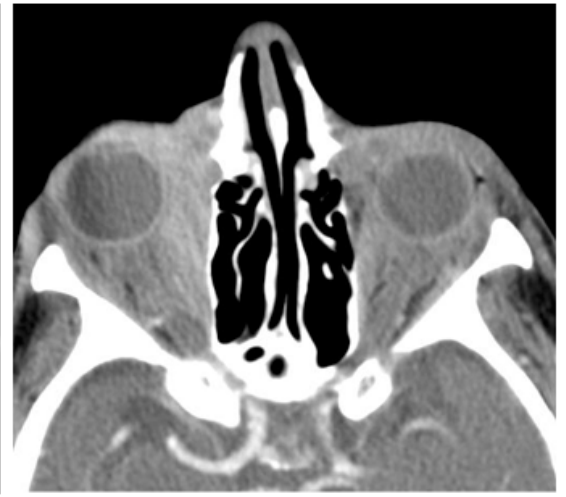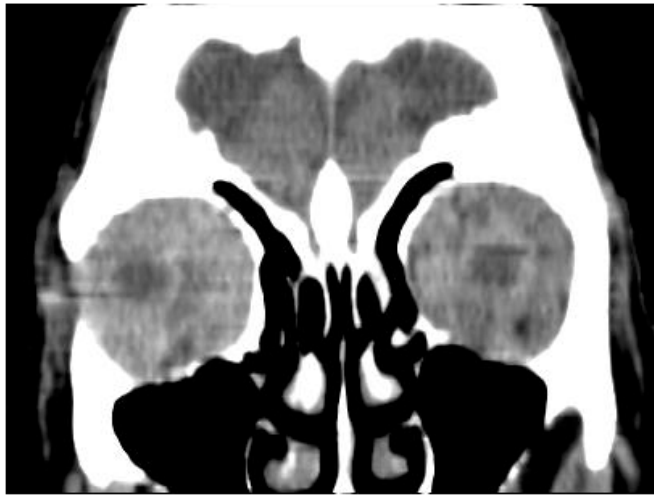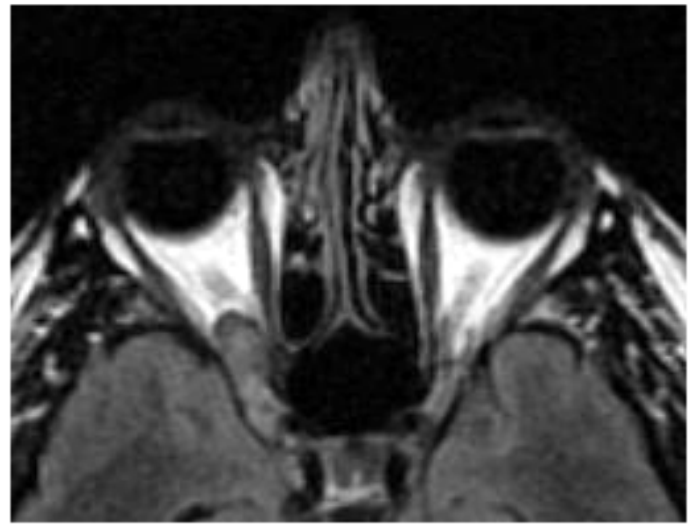
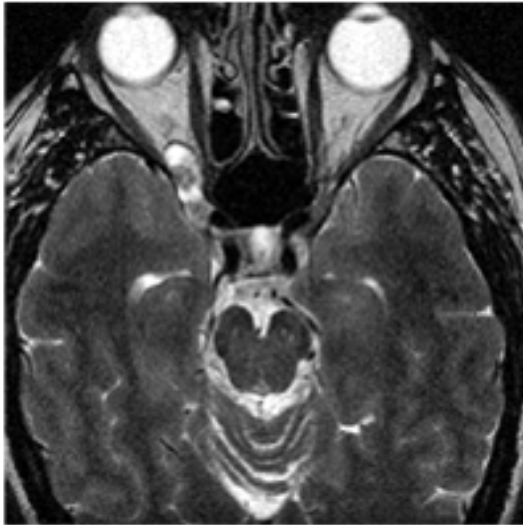
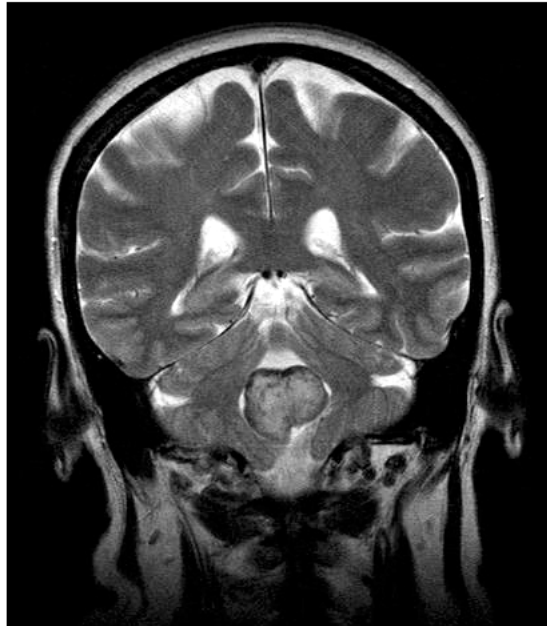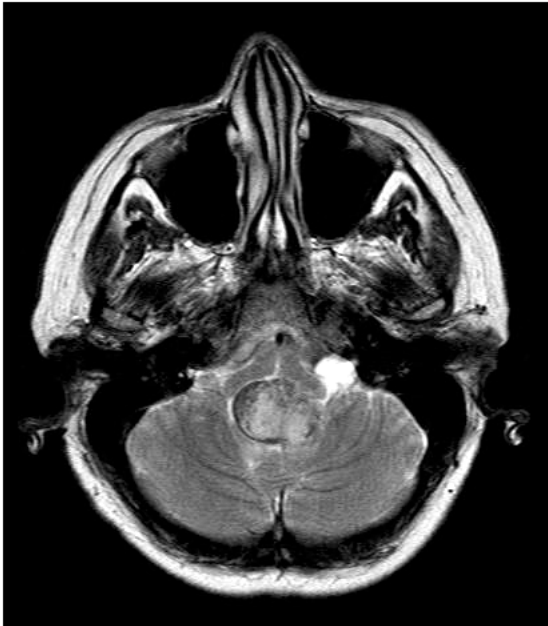




Dr Chankowsky: Bilateral orbital metastases from urinary bladder CA

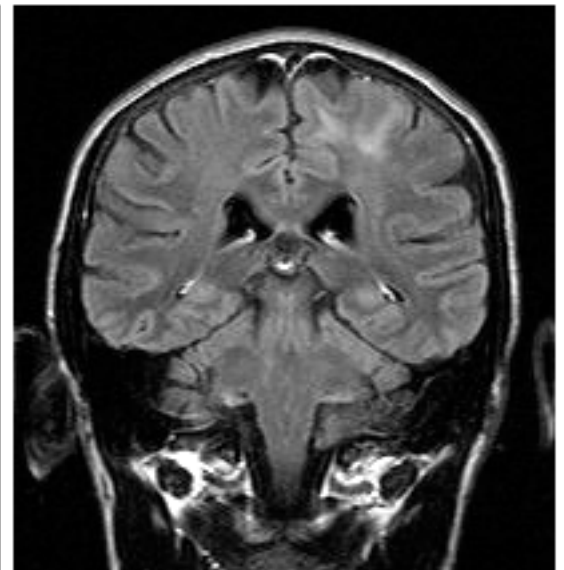
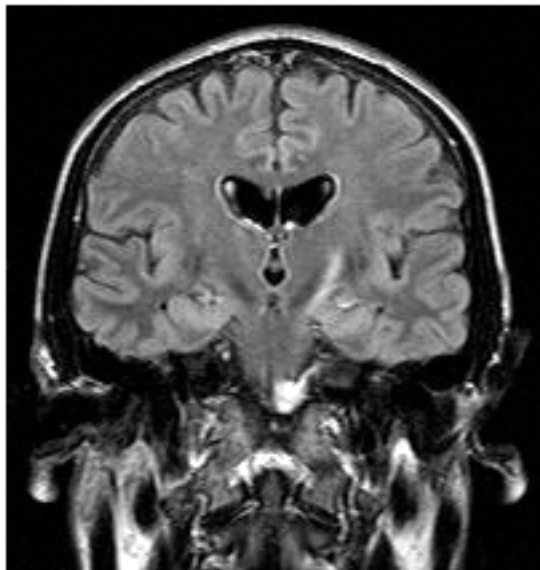


Dr Chankowsky: Orbital neurinoma (through right orbital fissure)



Dr Melançon: Meningioma in fourth ventricle

Dr Suzanne Fontaine:
AIDS patient with left parietal lesion and corticospinal tract lesion:
Wallerian degeneration or PML manifestation?



Cases discussed at the March Study Club ...

DR CHANKOWSKY

- ⌘ Orbital metastasis from urinary bladder CA
- ⌘ Orbital pseudotumour
- ⌘ Orbital neurinoma (through orbital fissure)
- ⌘ Occlusion of basilar artery
- ⌘ Right frontal infarct on CT diffusion (carotid dissection?)

DR ROBERTO WEE

- ⌘ Stenting the basilar artery: underestimated potential

DR O'GORMAN

- ⌘ MRI and MRA in estimating vascular anomalies

DR SUZANNE FONTAINE

- ⌘ Wallerian degeneration in AIDS patient: primary or secondary lesion?

DR MELANÇON

- ⌘ Thrombosis of Vein of Labbe-transverse sinus
- ⌘ Fourth ventricle meningioma

Those who attended the meeting:

Drs Wee, del Carpio, Chankowsky, Fontaine, Hall, Vezina, Ayala, Levental, Ender, O'Gorman, St-Onge, Melancon. Messieurs Franco d'Onofrio and Martin Campeau of Berlex Canada

We were very pleased to have Dr Roberto Wee, from the Ottawa General Hospital. He is one of the founding members of our Study Club, and he always brings his personal approach to diagnosis, a lesson to all of us.

PLEASE NOTE THAT THE MEETING NOW STARTS AT 6PM-18HRS and don't forget to sign the attendance sheet

You can bring your cases on films or CD's
R.S.V.P. by calling 398•1908 or faxing 398•2829

Amelio's pizzas will be on the menu, on a special request, for Dr Fontaine's 39th birthday.

FUTURE MEETINGS:
Another trip to Ottawa is in the planning • Berlex is looking at Redpath Museum as site of eventual CHUM-MUHC meeting

This study club is made possible from a generous contribution by Berlex Canada Inc.

BERLEX CANADA INC.

